

RESTORATIVE PROCEDURES - CROWNS -



CPD- 1 HOUR

Agenda/ Learning objectives:

- Reconstruction under existing crowns and cementing procedure
- Cementing of monolithic zirconia crowns
- Cementing of a pressed ceramic inlay

Outcomes:

By the end of this presentation the audience should be able to:

- understand the use of Visalys CemCore cement in 3 different case studies
- familiarize with the different techniques used during the 3 case studies

Summary of key information: Cementing procedures depend on different patient dental scenarios and the type of restorations, therefore by analyzing the 3 case studies presented here we're aiming to provide simple steps and solutions for addressing those type of clinical cases.

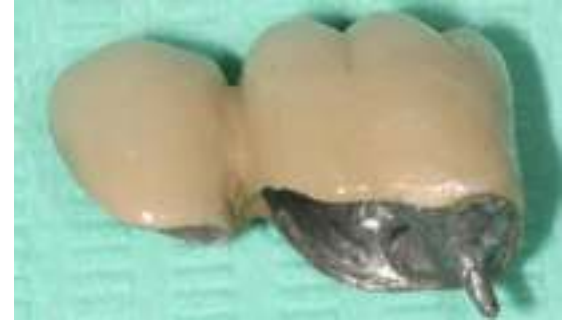Clinical case #1

Reconstruction under existing crowns and cementing procedure

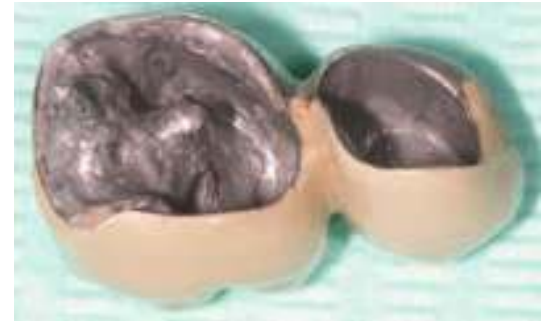(Dr Marc Apap)

INITIAL PRESENTATION

- Elderly patient who has already spent many sessions on the chair for the rehabilitation of the upper left quadrant
- His twin PFM (porcelain fused to metal) crowns on LL5 and LL6 have a correct morphology but loosen easily
- The crown on LL6 is a monolithic post and core PFM with a fairly short D root post,
- LL5 has a PFM with no post & core

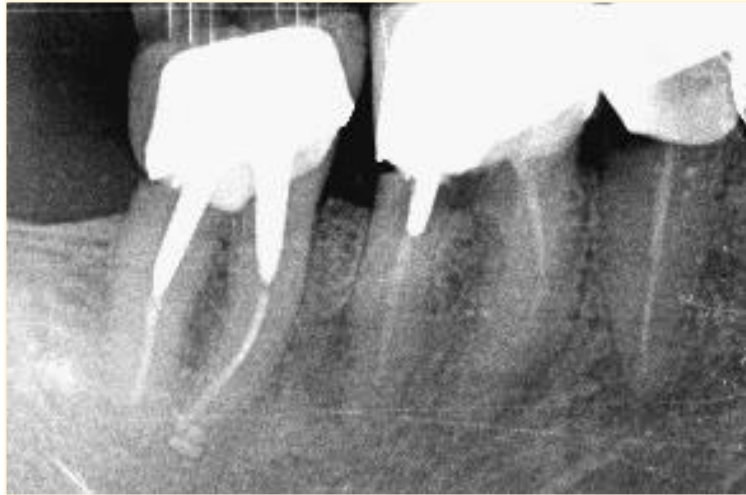

1



2

Support teeth show carious lesions, but sufficiently healthy hard tissues to be preserved



3 Preoperative X-ray showing carious lesions on LL5, LL6 & LL7

- The patient does not wish to undertake new long and costly prosthetic work.
- It was therefore decided to **keep the existing crowns** and to prepare the underlying dental tissues for a **direct composite restoration** under the crowns.
- The cement will both **restore the 3.5** and then, in a second step, **permanently fix the two crowns** on their dental support.

STEP 1

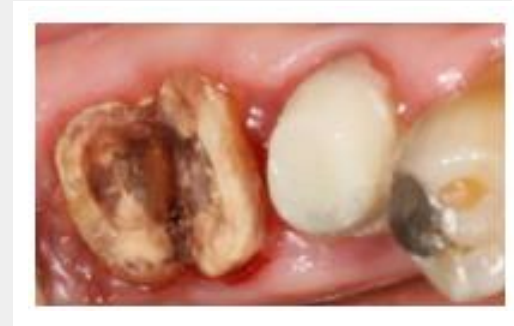Caries removal & gingivectomy

- The crowns are cleaned and freed of cement and dentin residues
- The carious dentin is removed
- A gingivectomy is performed for 3.5 & 3.6
- The two crowns are cemented with temporary resin cement until the soft tissues heal

STEP 2

Root post and core build-up on

- 3.5 15 days later, the crowns are removed and cleaned
- The root canal filling was prepared to receive a root post
 - Root post try-in and adjusted, then pre-treated with Visalys Restorative Primer
 - Visalys Tooth Primer was applied on the root canal walls & dentin surfaces, then dried with an air syringe
 - Visalys CemCore dual resin cement is applied into the canal and then inside the crown of 3.5 previously isolated with Vaseline
 - Root post inserted into root canal and crowns applied on 3.5 & 3.6 under finger pressure

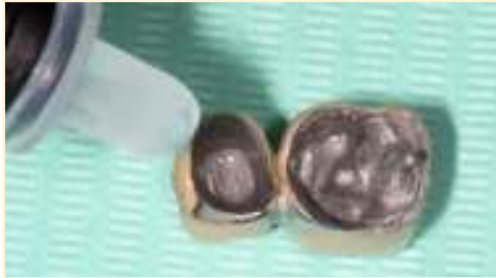

4

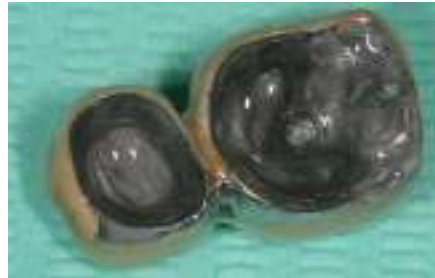STEP 3

Crown cementing

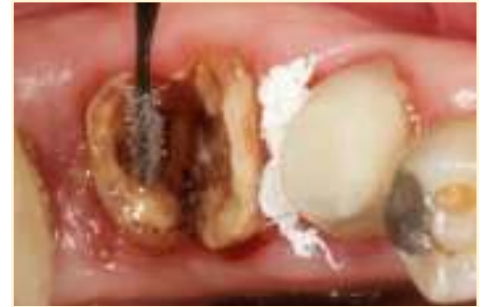- The crowns are removed and cleaned, just like the dental preparations.
- A pellet of Teflon® tape is wedged between 3.5 and 3.6
- Visalys Restorative Primer used to treat the inside of the crowns & the core of 3.5
- Visalys Tooth Primer used to treat the dentine of 3.6



5

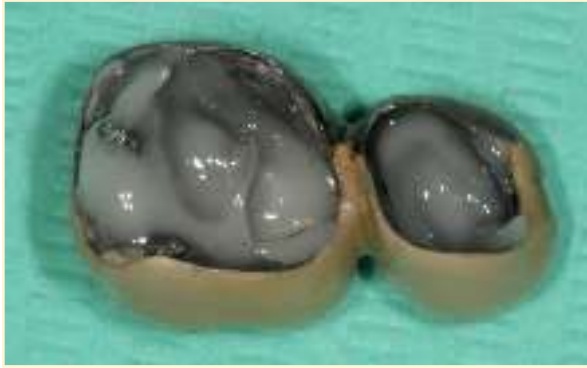


6

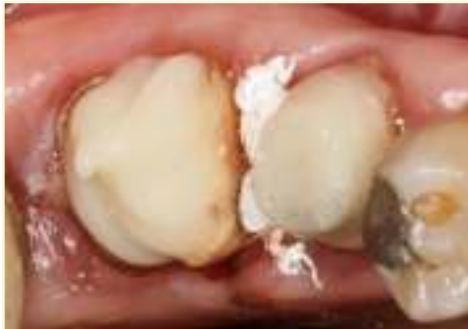

7

Visalys CemCore cement application
inside the crowns (8) and on 3.6 (9)

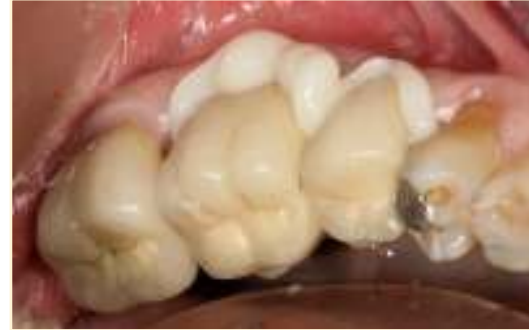

8



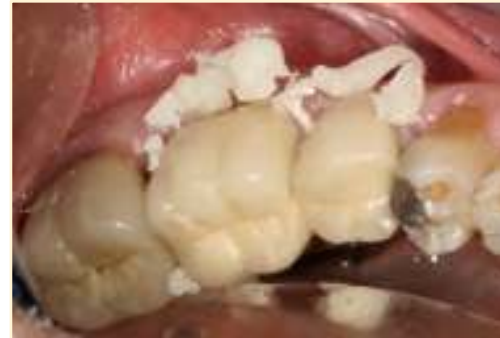9

Crown placement



10

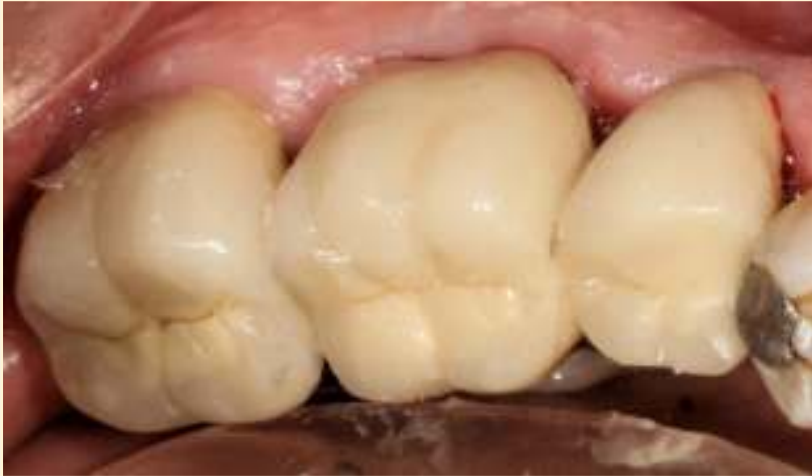Excesses removal



11

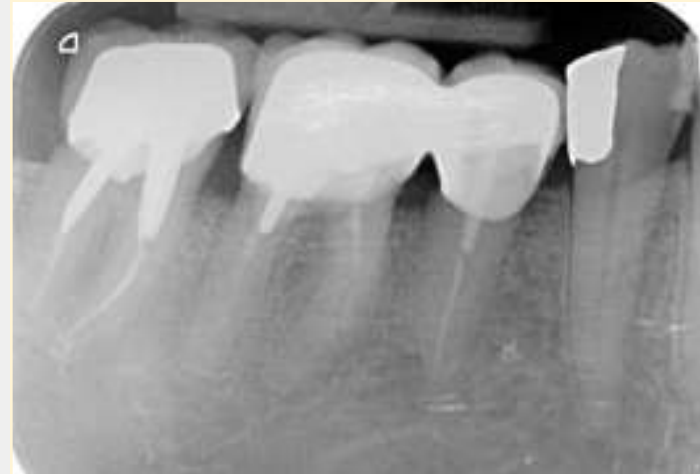
FINAL RESULT

Final result after complete removal of excess cement



12

Postoperative radiological control



13

https://www.kettenbach-dental.com/fileadmin/Produkte_COM/Visalys_CemCore/Studien/1410335_152_2_Visalys_CemCore_Studien_Rosentritt_EN.pdf

https://www.kettenbach-dental.com/fileadmin/Produkte_DE/Visalys_CemCore/Anwenderbericht/20200525_ZMK_VisalysCemCore_EN.pdf

Clinical case #2

Cementing of monolithic
zirconia crowns

(Dr Marc Apap)

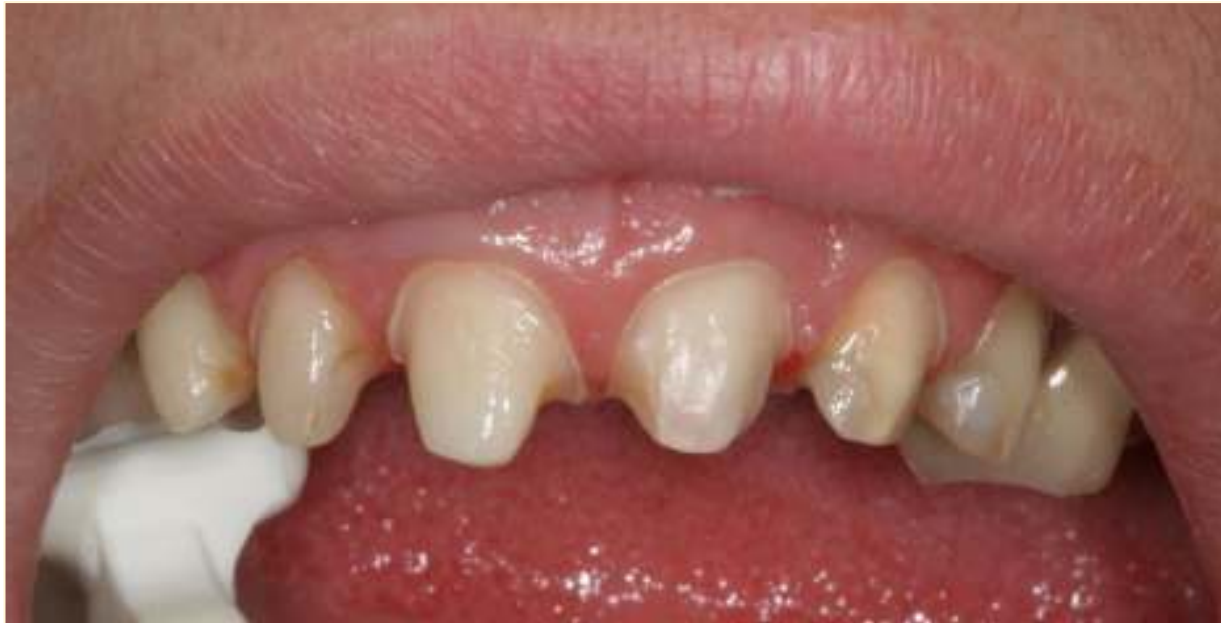INITIAL SITUATION

- Mrs. B. is a young mother who is not satisfied with her smile
- Her upper anterior teeth have been restored several times using increasingly large composite build-ups, which are now heavily discolored
- We decided to restore her vital upper anterior teeth using monolithic zirconia crowns
- Short and conic abutments due to extensive pre-existing restorations → splinted crowns

CEMENTING PROCEDURE STEP 1

sandblasting

Prepared teeth were cleaned, then light sandblasted and relative isolation achieved with cotton rolls

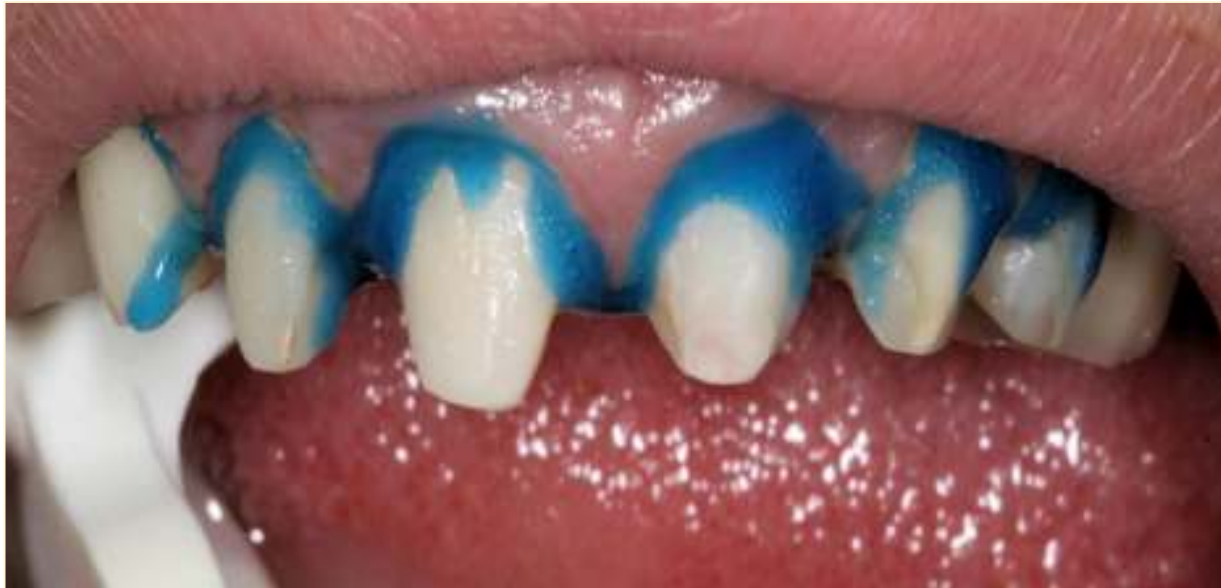

14

CEMENTING PROCEDURE STEP 2

etching

The peripheral enamel is etched with phosphoric acid for 30 seconds, then the preparations rinsed and gently dried

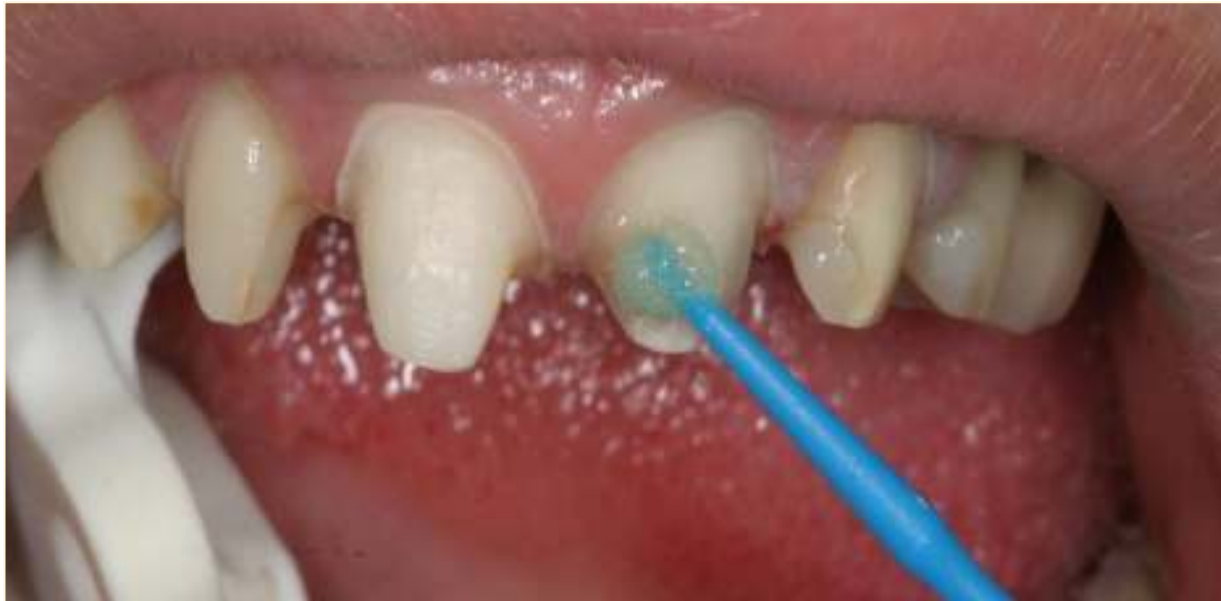

15

CEMENTING PROCEDURE STEP 3A

teeth priming

Visalys Tooth Primer applied for 20 seconds with a brushing technique & gently dried

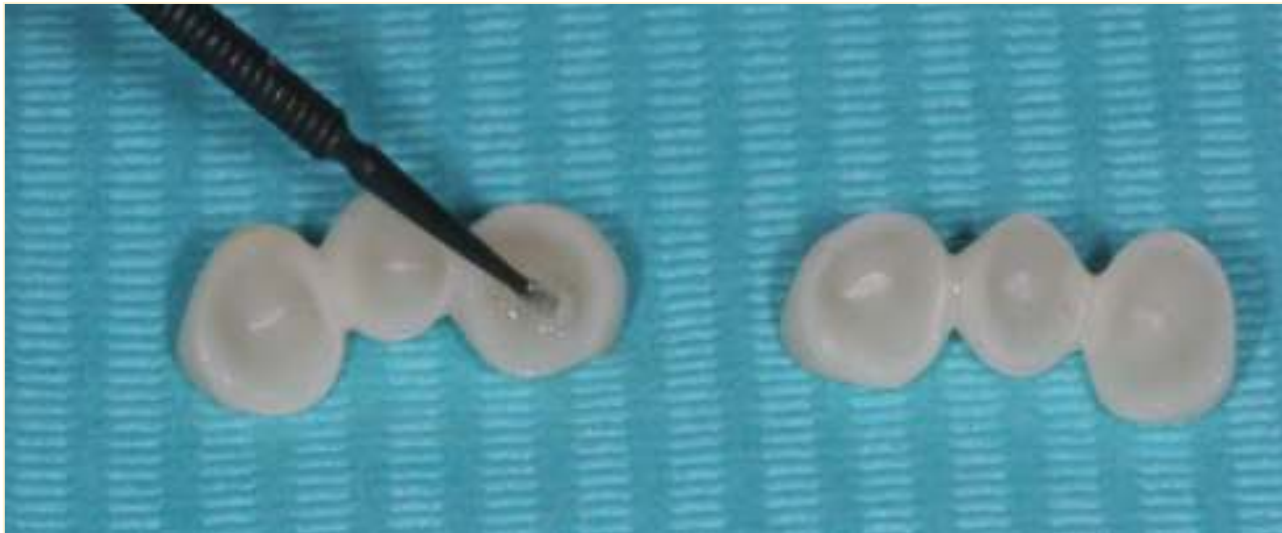


16

CEMENTING PROCEDURE STEP 3B

crowns priming

Visalys Restorative Primer applied inside the crowns for 20 seconds with a brushing technique & gently dried

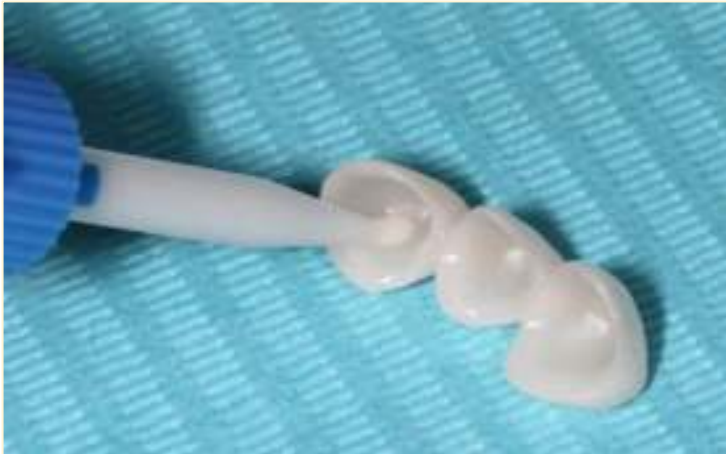

17

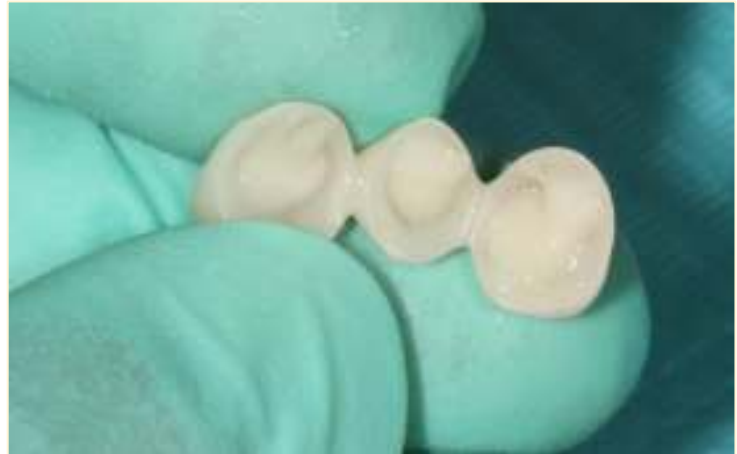CEMENTING PROCEDURE STEP 4

cement application

Using a self mixing tip Visalys CemCore is applied inside each crown



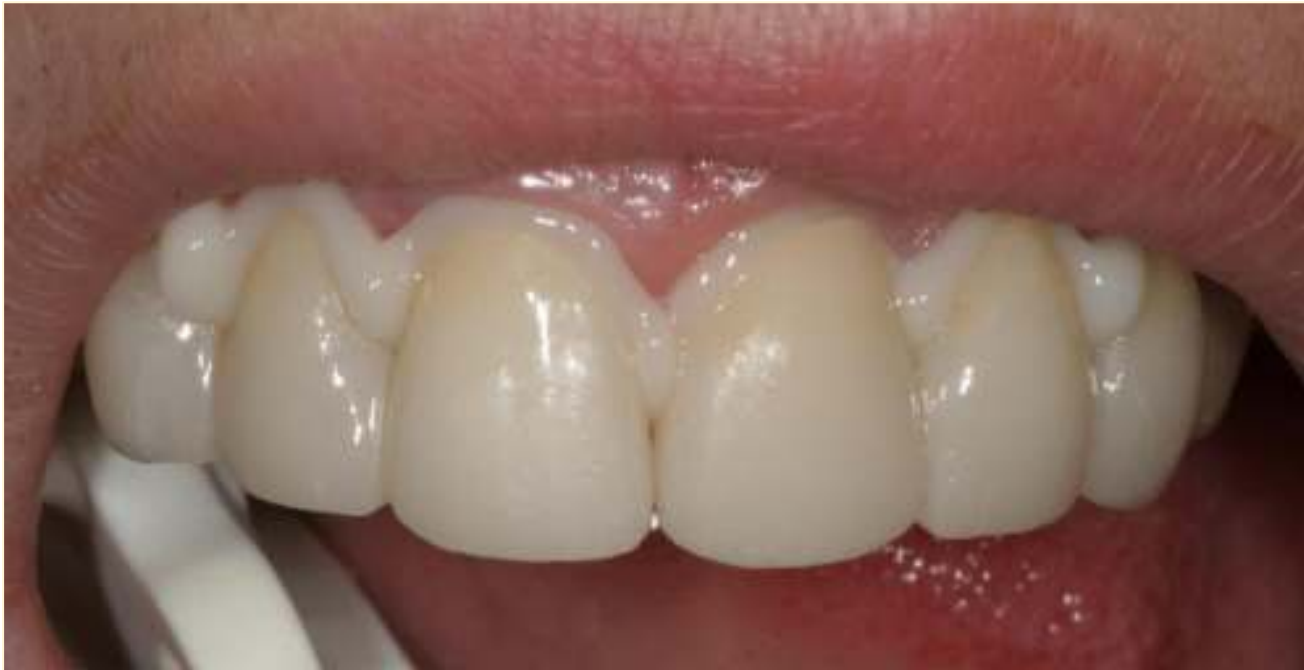18



19

CEMENTING PROCEDURE STEP 5

crown placement



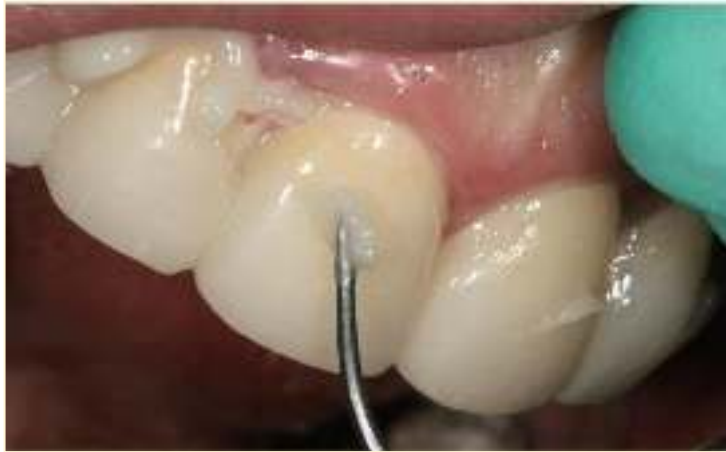20

CEMENTING PROCEDURE

STEP 6: excess removal (Fig. 21)

STEP 7: light-curing (Fig. 22)

After 1-2 minutes, eliminate excess with the probe



21

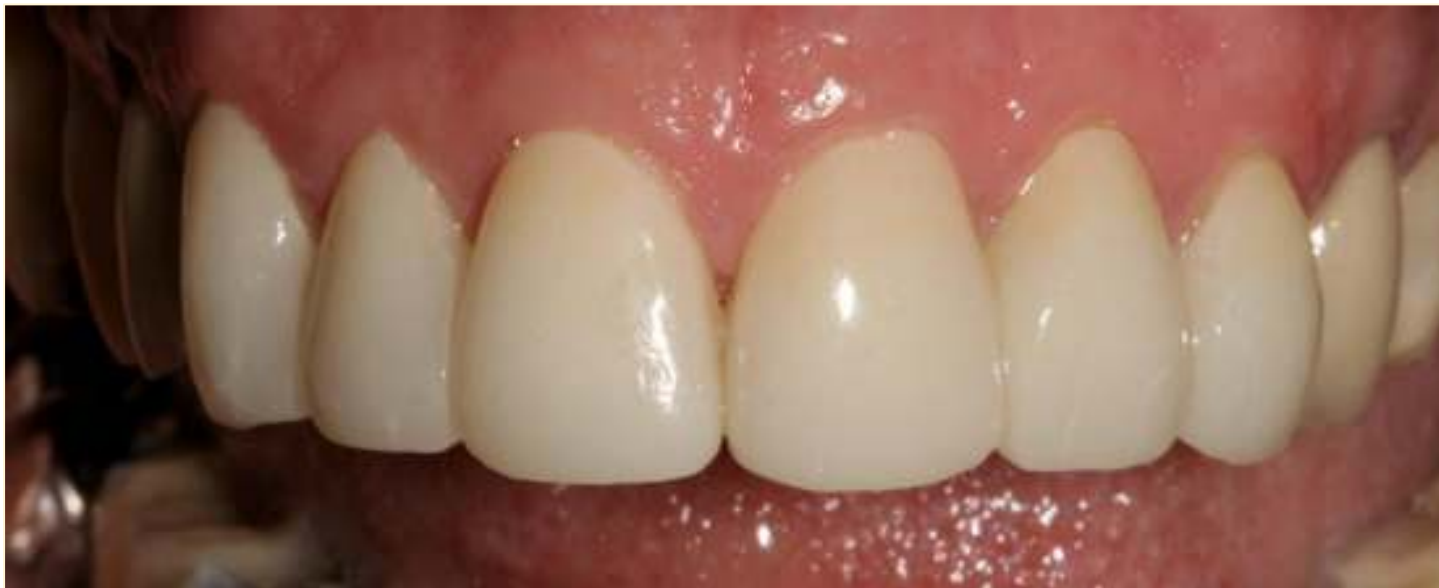Light-curing 40 seconds minimum on each side



22

FINAL RESULT

Control after 1 week



23

ADDITIONAL READING

https://www.kettenbach-dental.com/fileadmin/Produkte_COM/Visalys_CemCore/Studien/1410335_1522_Visalys_CemCore_Studien_Rosentritt_EN.pdf

https://www.kettenbach-dental.com/fileadmin/Produkte_DE/Visalys_CemCore/Anwenderbericht/20200525_ZMK_VisalysCemCore_EN.pdf

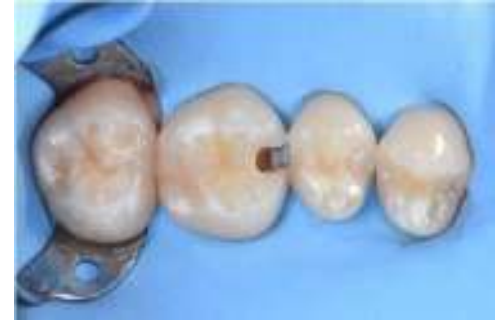Clinical case #3

Cementing of a pressed ceramic inlay

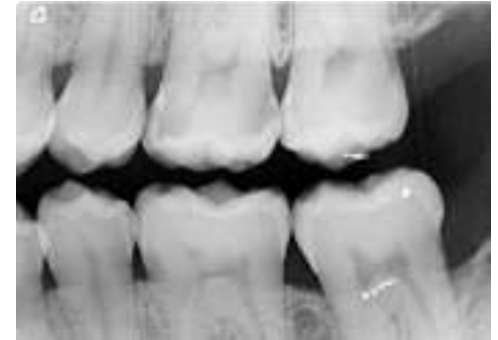(Dr Florian Apap)

INITIAL SITUATION

- Mr L., 28 years old, unhappy because of repeated food impaction mesial of 2.6
- X-ray also revealed the presence of a large distal carious lesion on the same tooth
- After removal of the carious hard tissues, it was decided to perform a pressed ceramic MOD inlay (E.max ®) to restore this molar

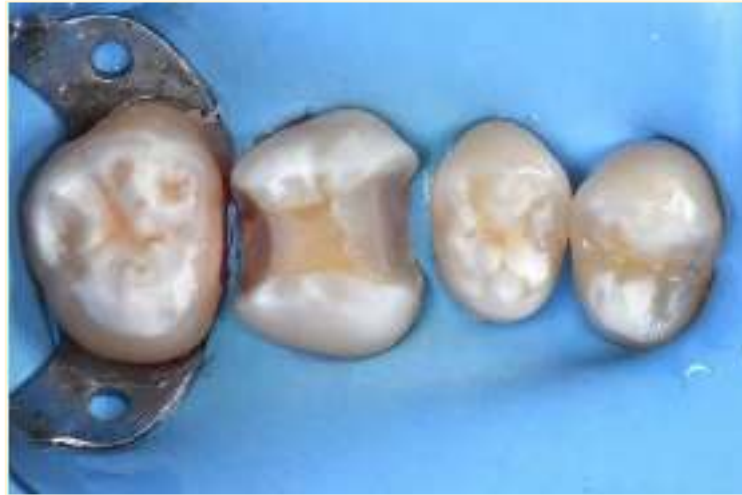

24 Initial clinical situation



25 Preoperative X-ray

Pulp protection and Immediate dentine sealing (IDS) on axial walls under rubber dam isolation



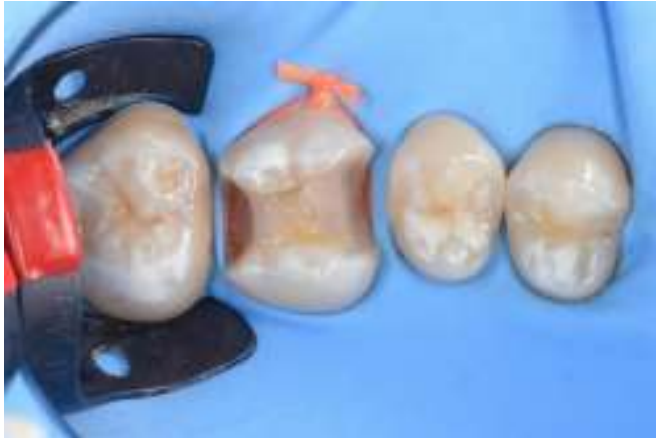26

CEMENTING PROCEDURE STEP 1

etching

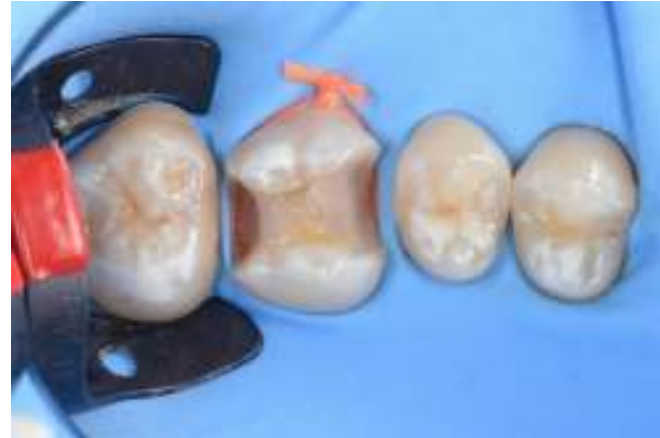Good isolation of working area its of extreme importance – rubber dam application

Rubber dam in place



29

Enamel etching

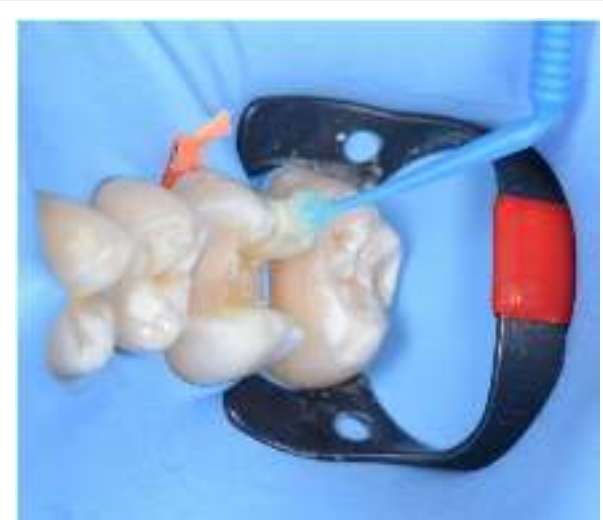

30

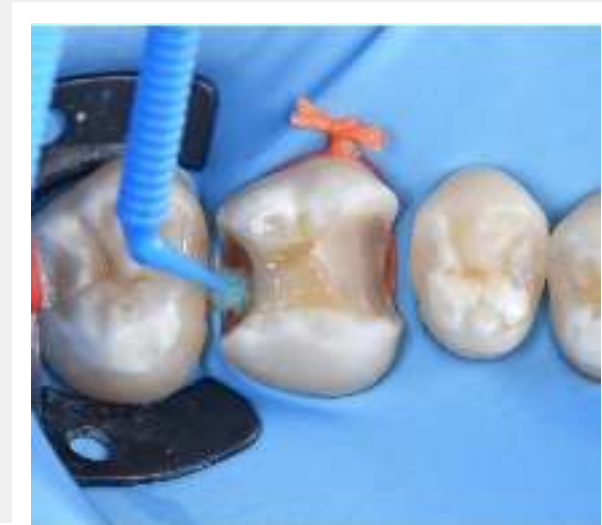CEMENTING PROCEDURE STEP 2

tooth priming

Visalys Tooth Primer application



31



32

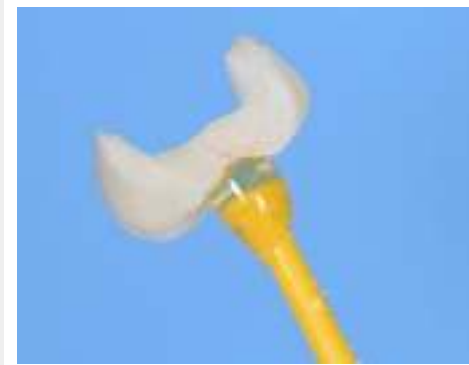CEMENTING PROCEDURE STEP 2B

inlay priming

Visalys Tooth Primer application

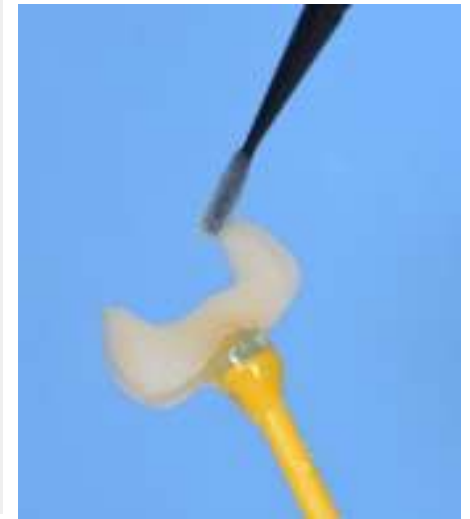

33 Etching of the inner surface with hydrofluoric acid



34 Rinsing, drying

35 Visalys Restorative Primer application



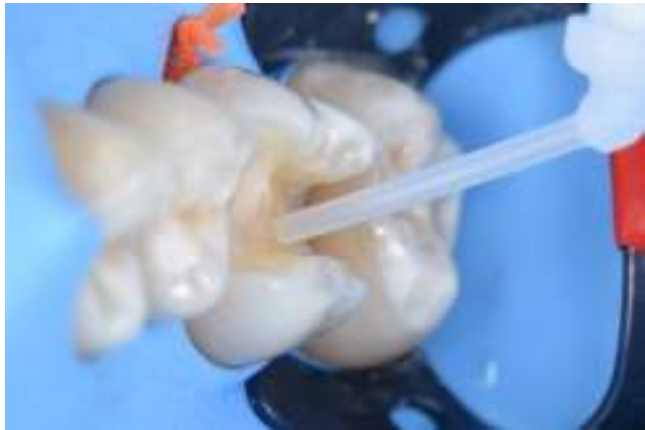CEMENTING PROCEDURE

STEP 3: cement application (Fig. 36)

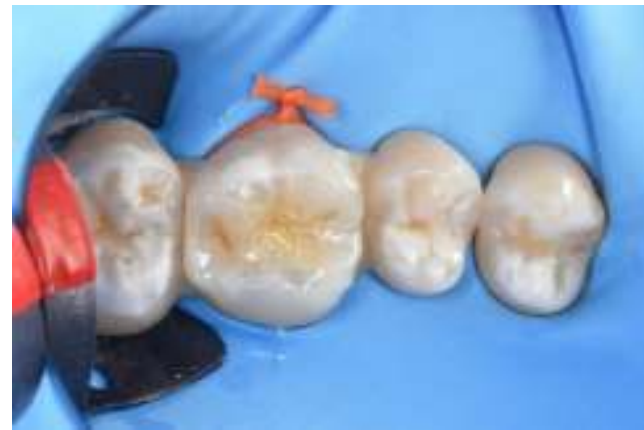STEP 4: inlay placement (Fig. 37)

STEP 5: excess removal

STEP 6: dual curing (with or without light-curing)



36

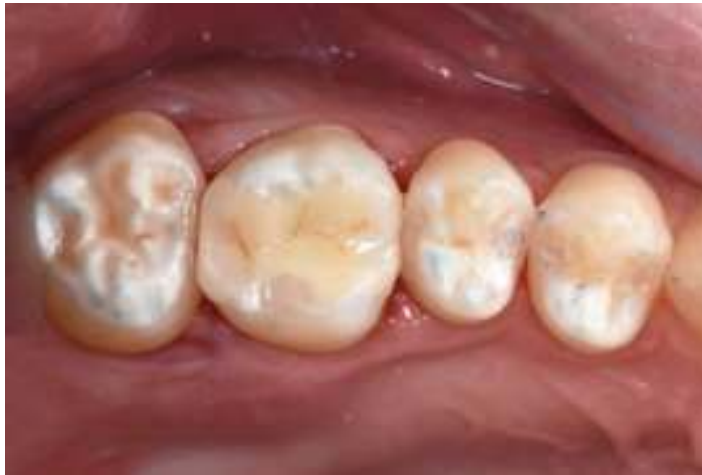

37

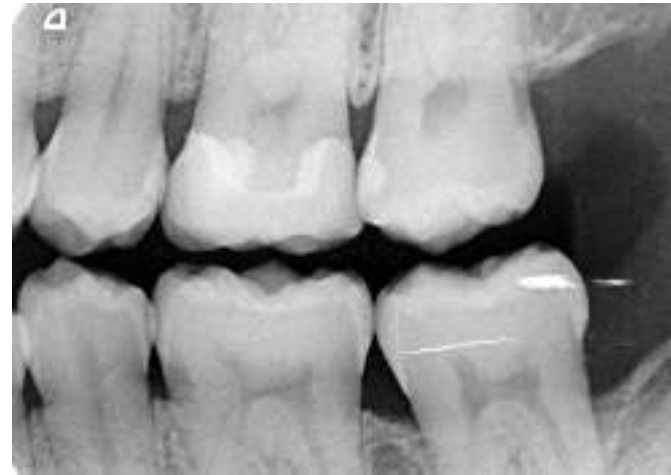FINAL RESULT

Control after 1 week

Final result after occlusal adaptation



X-ray image after cementing



https://www.kettenbach-dental.com/fileadmin/Produkte_COM/Visalys_CemCore/Studien/1410332_1522_Visalys_CemCore_Studien_Frankenberger_EN_01.pdf

[1] Scientific report: "Push-out bond strength evaluation of Visalys Core in root canals", Prof. Dr. Roland Frankenberger, 2015, Universität Marburg

[2] Scientific report: "Improved dentin bonding of core build-up composites using Visalys Core", Prof. Dr. Roland Frankenberg, 2015, Universität Marburg

[3] Scientific report: „(39) -Support de Cours (Version PDF) – Les systèmes adhésifs amélo- den naires", ILHAM KARA - Academia.edu

[4] Scientific report: Oper Dent. 2014 Jan-Feb; 39(1):E31-44. doi: 10.2341/13-070-LIT. Epub 2013 Aug 12. The role of resin cement on bond strength of glass-fiber posts

luted into root canals: a systematic review and meta-analysis of in vitro studies. Sarkis-Onofre R, Skupien JA, Cenci MS, Moraes RR, Pereira-Cenci T.

[5] Scientific report: Materials (Basel). 2019 Mar; 12(5): 790. doi: 10.3390/ma12050790. 10-MDP Based Dental Adhesives: Adhesive Interface Characterization and Adhesive Stability – A Systematic Review Eunice Carrilho, Miguel Cardoso, Manuel Marques Ferreira, Carlos Miguel Marto, Anabela Paula, and Ana Sofia Coelho

THANK YOU!

[GO TO EVALUATION FORM](#)



KETTENBACHDENTAL