

# Technical Manual Kettenbach Dental

# **The Trouble Shooting Guide - Most frequent mistakes in impressions taking**

**Elastomeric dental impression materials  
VPS – addition curing silicones**

# Contents

- 01 Inadequate margins
- 02 Tearing
- 03 Tearing / rough surfaces
- 04 Voids & bubbles
- 05 Pulls & drags
- 06 Washing / syringing of the preparation
- 07 Biological space requirement
- 08 De-lamination / lack of co-adaptation
- 09 Tray seating
- 10 Ledges
- 11 Inadequate tray adhesion
- 12 Glove & hemostatic agent selection
- 13 Surface inhibition / wash slow setting
- 14 Not enough wash material & Tooth contact with tray
- 15 Tight fitting crowns
- 16 Double bite technique
- 17 Panasil
- 18 Bite registration
- 19 Patient education
- 20 Seating and removal of the tray



**KETTENBACHDENTAL**

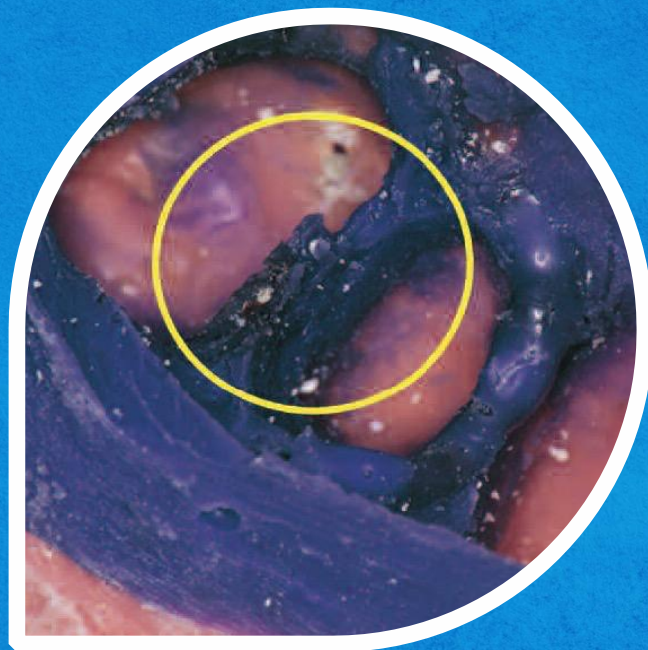
Simply intelligent

# 01 INADEQUATE MARGINS

# 01 INADEQUATE MARGINS

## PROBLEM

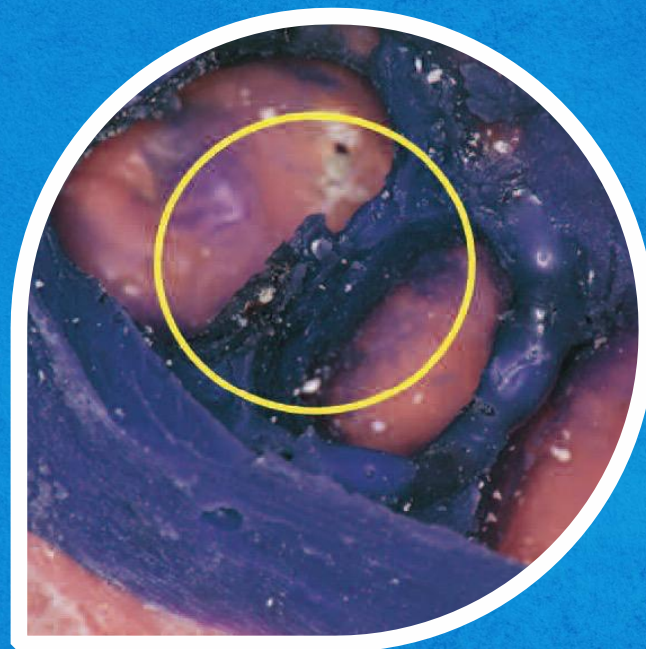
- Insufficient Tissue Management
- Insufficient wash material
- Tip not continually submersed within impression material and sulcus
- Tearing of the margin
- Exceeding working time of material
- May require additional tooth preparation for adequate sulcus width



# 01 INADEQUATE MARGINS

## PROBABLE CAUSES

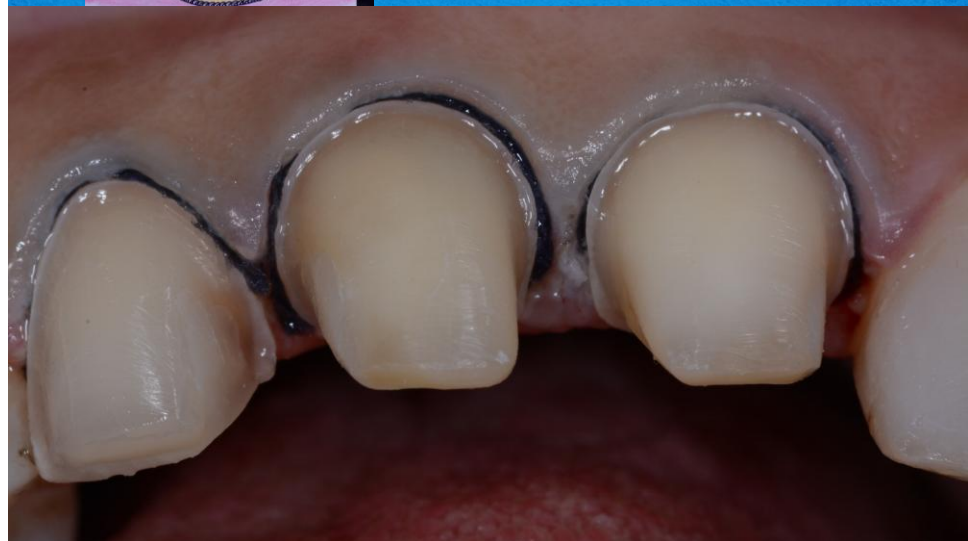
- Inadequate retraction of sulcus around the prep
- Moisture or bleeding around the prep
- Too much time between mixing and seating
- Rocking of tray to get proper seating
- Tray movement after it has been seated



# 01 INADEQUATE MARGINS

## SOLUTION

- Ensure good tissue management. At least 0.5 mm apical and 0.5mm laterally. No gingivitis or “pumping” sulcus. Clean field is critical. Double cord may alleviate.
- Keep syringe tip immersed in material and sulcus and push the material 360 degrees around sulcus.
- Use wash material that has higher tear strength properties.
- Seat Regular Set material within 1 min and Fast Set material within 30 seconds.





**KETTENBACHDENTAL**

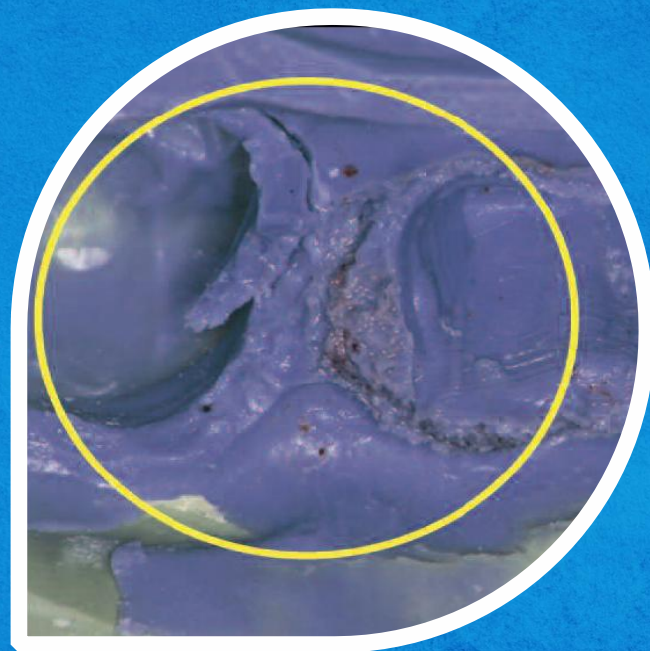
Simply intelligent

# 02 TEARING

# 02 TEARING

## PROBLEM

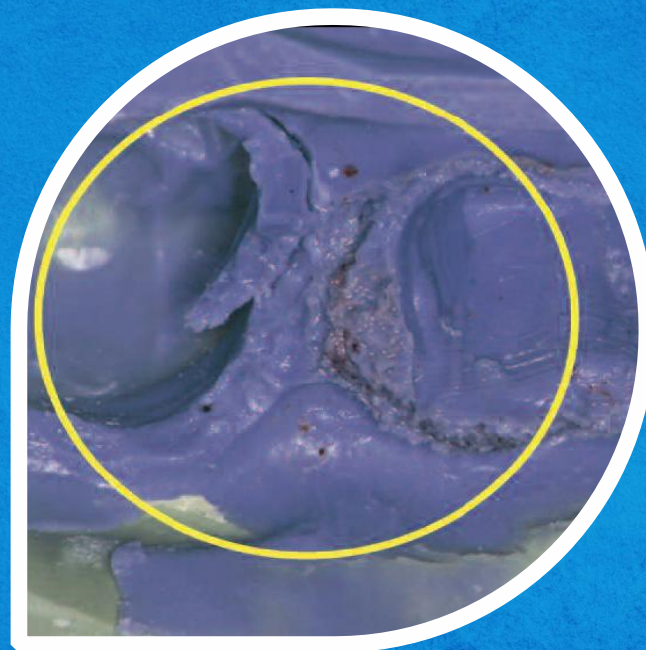
- Poor tear strength of impression material
- Inadequate space created during retraction
- Premature removal from mouth
- Inadequate blocking of severe undercuts
- **NOTE:** Torn margin of a PVS impression will have a dull/matt appearance.



# 02 TEARING

## PROBABLE CAUSES

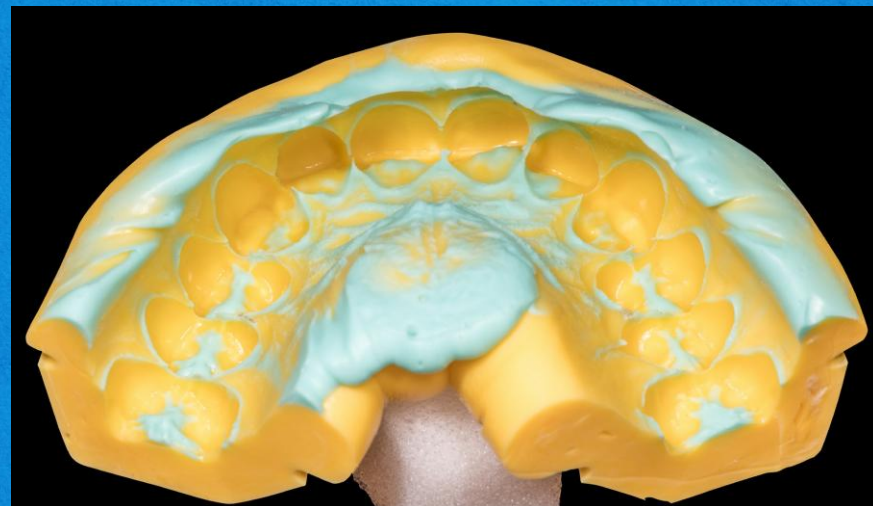
- Premature removal of tray from the mouth; inattention to recommended times
- Inadequate retraction of sulcus around the prep



# 02 TEARING

## SOLUTION

- Ensure > 0.5 mm of lateral retraction circumferentially around finish line. The greater the bulk of impression material the more resistance to tearing.
- Use a timer to ensure the setting reaction from time of mix is complete. An additional safeguard would be to check the set of the peripheral areas of the impression prior to removal.
- Block severe undercuts with easily removable material such as soft wax.





**KETTENBACHDENTAL**


Simply intelligent

# 03 TEARING / ROUGH SURFACES

# 03 TEARING / ROUGH SURFACES

## PROBLEM

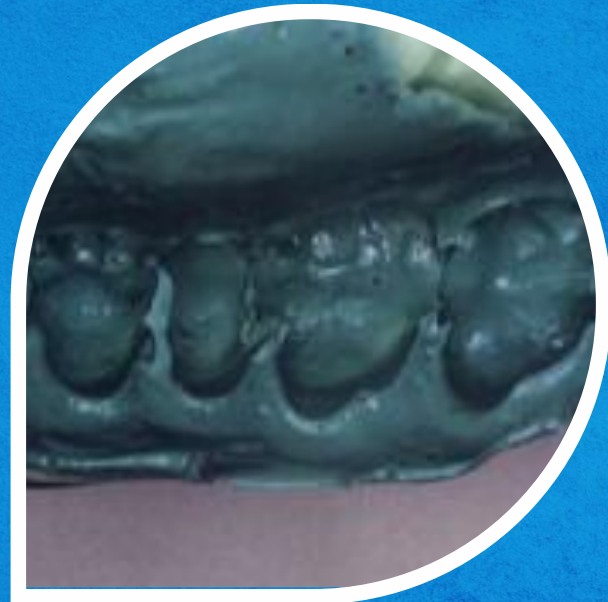- Rough occlusal and/or incisal surfaces and tearing visible on the margin of the preparation.
- Poor lamination between tray material and wash may also be evident.



# 03 TEARING / ROUGH SURFACES

## PROBABLE CAUSES

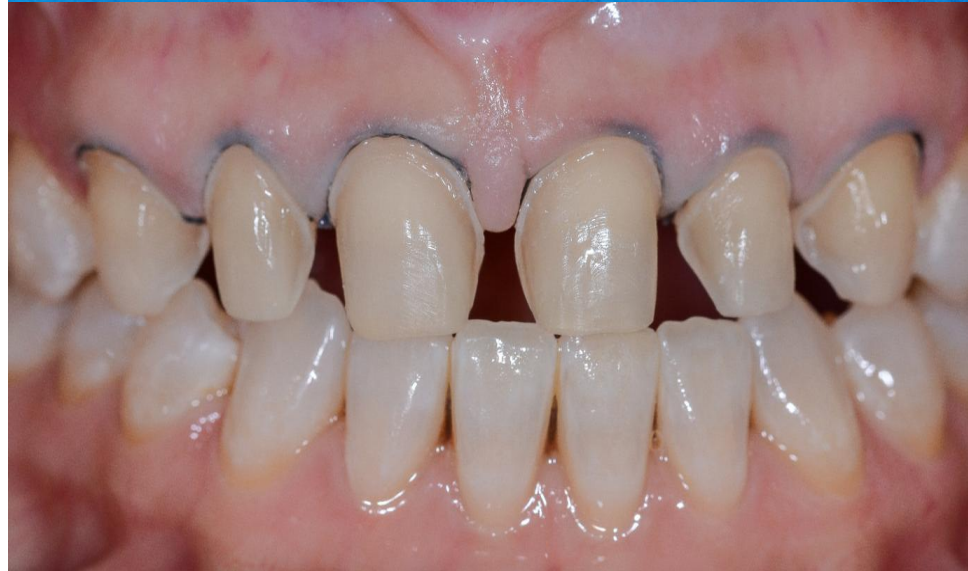- Poor retraction technique
- Surface inhibition
- Moisture present
- Material slow setting (reason unknown)
- Wash partially set at tray seating
- Early mouth removal



# 03 TEARING / ROUGH SURFACES

## SOLUTION

- Improve retraction, and where appropriate, consider the two-cord retraction technique.
- Control bleeding and avoid pools of water or saliva on occlusal surfaces.
- Closely follow recommendations for working time.
- Set a timer to ensure that the impression remains in the mouth for the full recommended set time.





**KETTENBACHDENTAL**


Simply intelligent

# 04 VOIDS & BUBBLES

# 04 VOIDS & BUBBLES

## PROBLEM

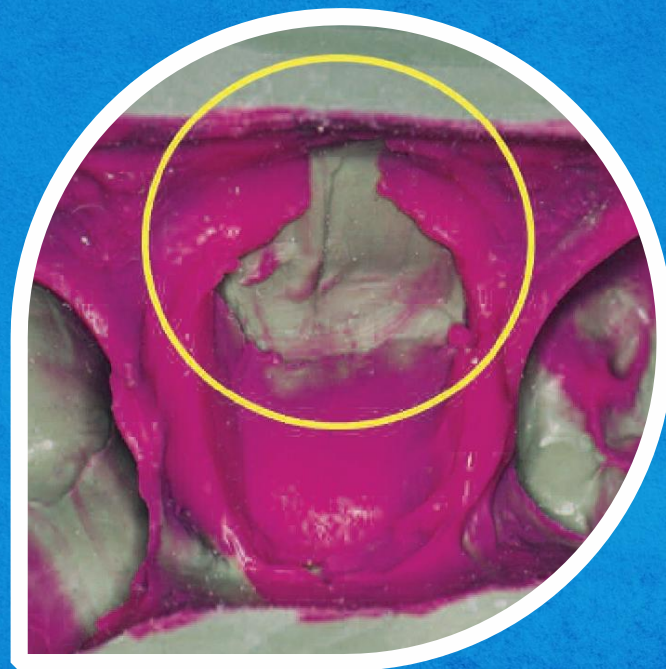
- Improper syringe technique.
- Air incorporated into syringe while loading material into syringe or tray.
- Remains of blood/saliva around preparation.
- Voids on the margin of a preparation compromise the fit and function of the final restoration (photo).
- Voids on occlusal surfaces make articulation of stone models difficult.



# 04 VOIDS & BUBBLES

## PROBABLE CAUSES

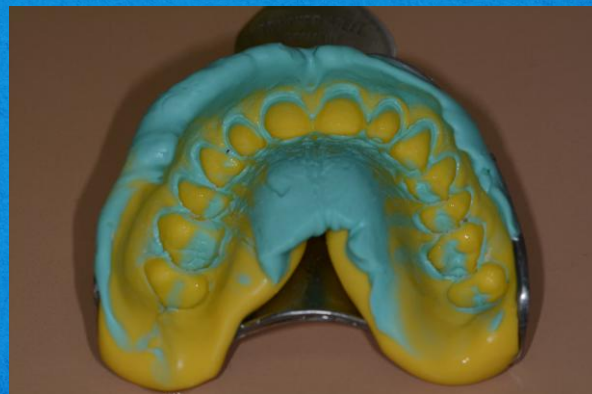
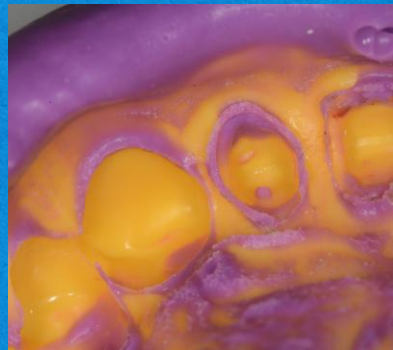- Air incorporated when loading intraoral syringe.
- Moisture present either in the sulcus, or pooled on occlusal surfaces.
- Inadequate retraction of sulcus around the prep.
- Too much time between mixing and seating.
- Improper syringing technique around prep; keep tip immersed and use stirring motion.



# 04 VOIDS & BUBBLES

## SOLUTION

- Voids may be reduced by using a stirring motion while syringing, keeping the syringe tip immersed to avoid trapping air.
- Ensure no excess/pooling of moisture and control bleeding.
- Rinse retraction cord thoroughly prior to removal to eliminate sulfur based contaminants from hemostatic agent or glove.
- If using a syringe, front load syringe by inserting mix tip directly into intraoral syringe and forcing the plunger backwards.

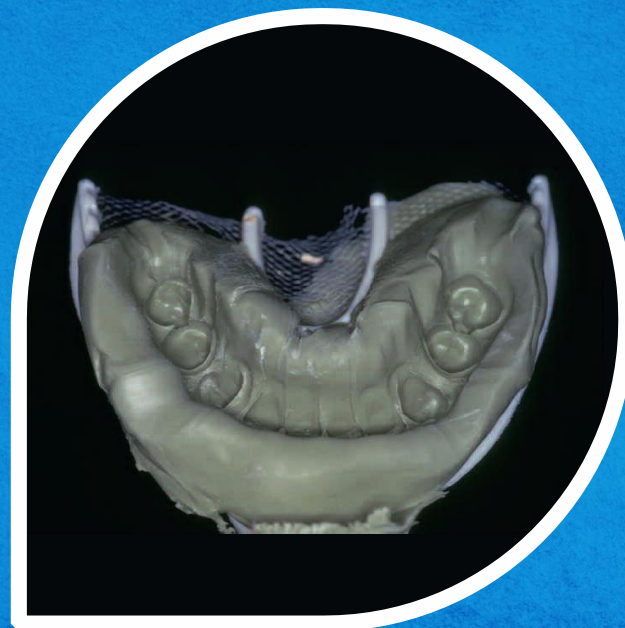

# 05 PULL & DRAGS

# 05 PULL & DRAGS

## PROBLEM

- Timing of wash and tray materials not synchronized.
- Tray seated too late.
- Tray movement during impression material setting reaction.



# 05 PULL & DRAGS

## SOLUTION

- Carefully read manufacturer instructions.
- Room or material temperature too high.





**KETTENBACHDENTAL**

Simply intelligent

# 06 WASHING / SYRINGING OF THE PREPARATION

# 06 WASHING / SYRINGING OF THE PREPARATION

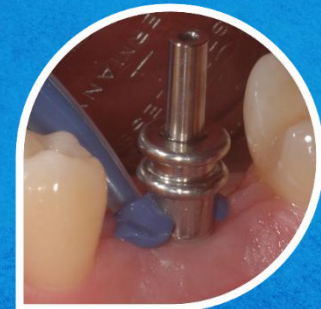
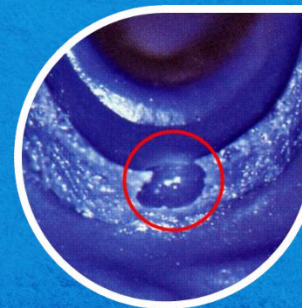- **If time permits, use a syringe as it is ideal for access to the sulcus and tactile feedback.**
- **Begin syringing the preparation. At the same time the assistant should be loading the tray.**
- **Continue syringing around the preparation while pushing the material forward and keeping the tip buried in the material.**
- **When approaching interproximal areas it may be necessary to express material thru the interproximal and continue injecting into the sulcus on the opposite side of the proximal area.**

# 06 WASHING / SYRINGING OF THE PREPARATION

- **When coverage of the marginal area is completed, proceed coronally and circumferentially using the same principle of keeping the tip buried and pushing the material forward.**
- **Remove the tip from the material after prep and each adjacent occlusal/incisal surface is entirely covered with wash material.**
- **Some clinicians have found benefit from placing a layer of wash on the tray material prior to seating.**
- **Seat the tray as soon as you are finished syringing the preparation to ensure no folds, pulls, drags and good co-lamination.**

# 06 WASHING / SYRINGING OF THE PREPARATION

- The wash was not injected correctly around the implants and the impression tray was inserted in the mouth when the material was already in the polymerization phase, losing its fluidity.



# 07 BIOLOGICAL SPACE REQUIREMENT

# 07 BIOLOGICAL SPACE REQUIREMENT

- Generally need at least 3 mm from the margin of the restoration (Finish Line) to the Alveolar Crest.
- If current conditions do not allow for this amount space, surgical or orthodontic remedies should be explored.





**KETTENBACHDENTAL**

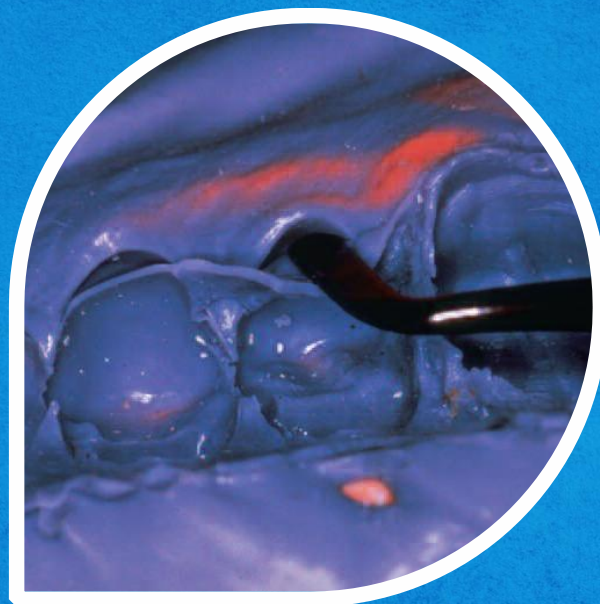
Simply intelligent

# 08 DE-LAMINATION / LACK OF CO-ADAPTATION

# 08 DE-LAMINATION / LACK OF CO-ADAPTATION

## PROBLEM

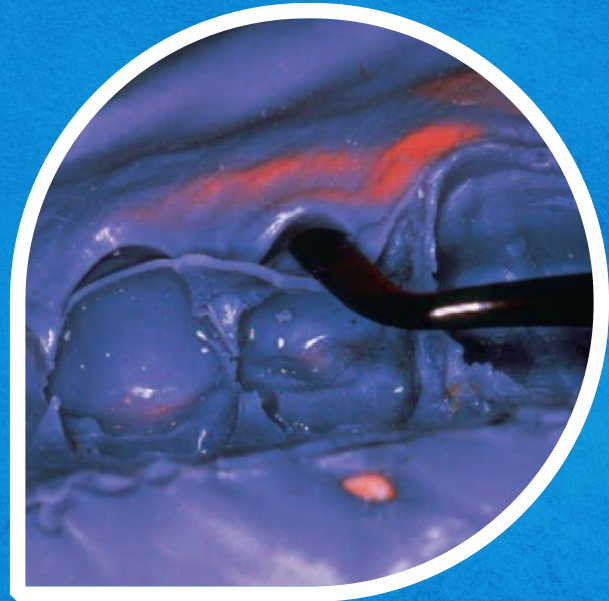
- Timing of wash and tray materials not synchronized
- Material not setting
- Latex contamination
- Provisional residual from oxygen inhibition layer
- Blood/saliva/water contamination especially with a two-step technique when a spacer is not used
- Relining of impression with wash material



# 08 DE-LAMINATION / LACK OF CO-ADAPTATION

## PROBABLE CAUSES

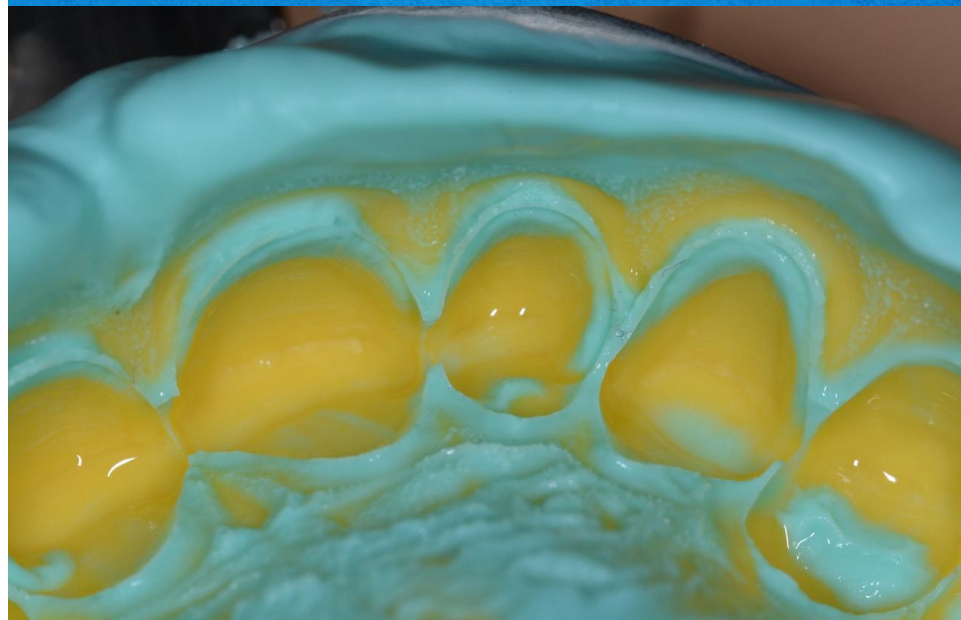- Contamination of vaseline / balm used on syringe or lips
- Glove contamination
- Outdated / expired impression materials
- Reline of impression



# 08 DE-LAMINATION / LACK OF CO-ADAPTATION

## SOLUTION

- Seat Regular Set material within 1 min. and Fast Set material within 30 sec.
- Use a spacer for Two Step techniques
- Latex gloves should not touch material
- Ensure proper isolation
- Do not use the same impression in a two step technique for the provisional matrix and the final impression
- Do not reline as it does not provide proper co-lamination and will distort the impression.
- Clean impression with water and air dry before using wash material.





**KETTENBACHDENTAL**

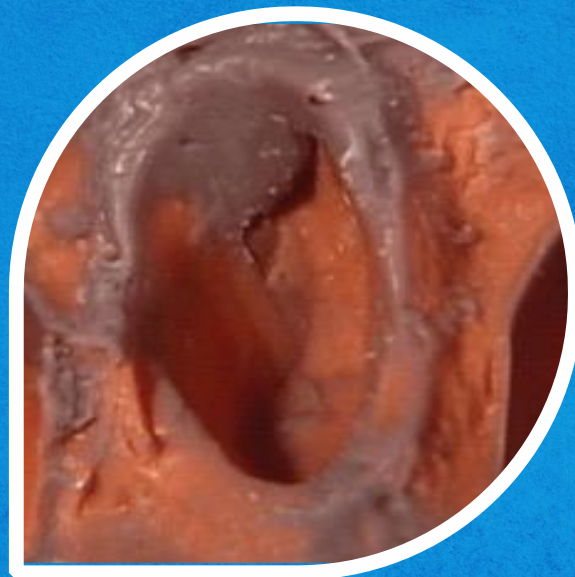Simply intelligent

# 09 TRAY SEATING

# 09 TRAY SEATING

## PROBLEM

- Delamination (poor blending and adhesion of wash to tray material)
- Slanted or wavy teeth
- Rocking crown
- Short crowns



# 09 TRAY SEATING

## PROBABLE CAUSES

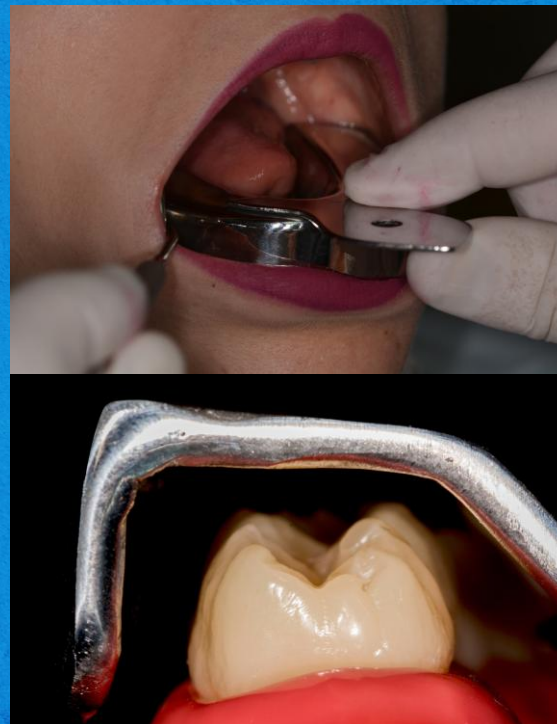
- Rapid tray seating
- Placing and seating the tray in the mouth in one motion
- Failure of the impression material to adapt to the teeth
- Teeth rebounding off the tray and sliding into position
- Tray movement after seating
- Teeth in contact with tray and/or not adequately relieving pre-set impression material



# 09 TRAY SEATING

## SOLUTION

- Carefully position the tray before seating.
- Use a slow, steady, vertical seating motion to allow for blending of tray/wash materials.
- Once positioned, seat the tray vertically.
- Seat the tray slowly.
- Avoid contact of teeth with tray.
- After tray seating, use passive pressure to immobilize the tray for the full recommended oral set time.
- Avoid contact of teeth with tray or pre-set tray material.





**KETTENBACHDENTAL**

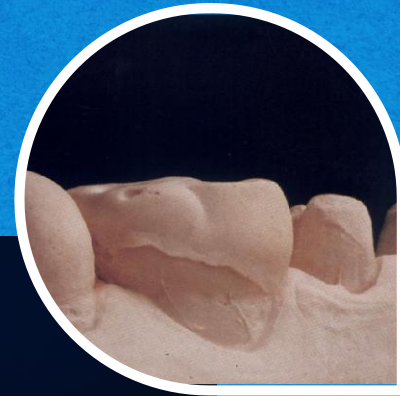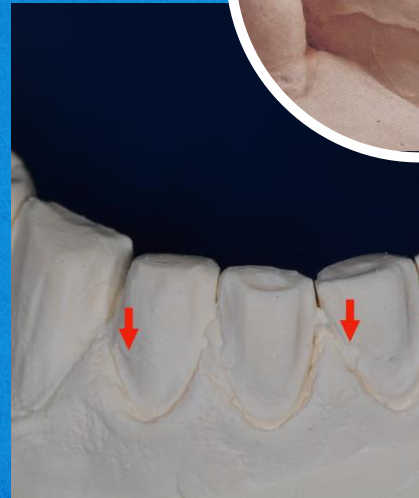Simply intelligent

# 10 LEDGES

# 10 LEDGES

## PROBABLE CAUSES

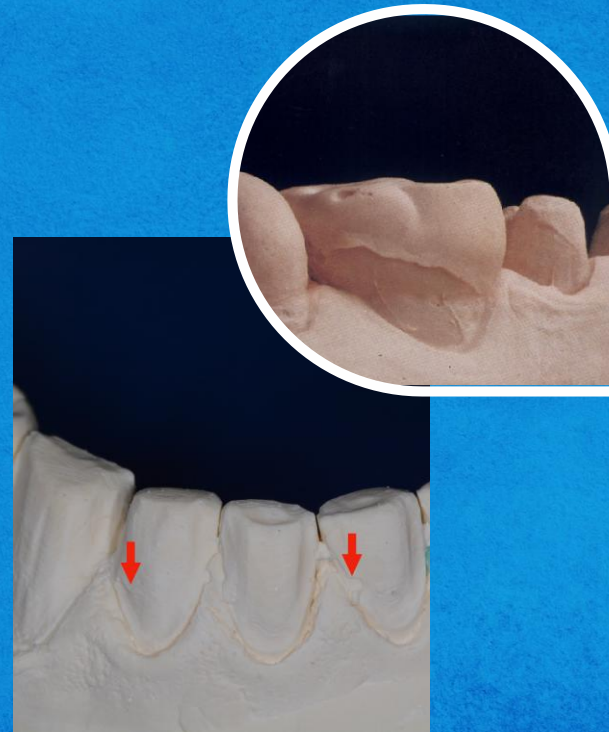- Dimple in putty material is too small; must be deep and include teeth adjacent to all preps
- Tray dislodges before material fully set
- Not enough wash material
- Tray seated too quickly / forcefully



# 10 LEDGES

## SOLUTION

- Dimple in putty material is too small; must be deep and include teeth adjacent to all preps
- Tray dislodges before material fully set
- Not enough wash material
- Tray seated too quickly / forcefully





**KETTENBACHDENTAL**

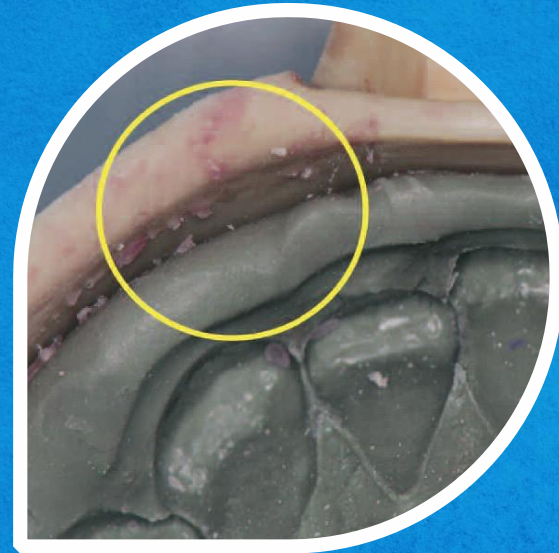Simply intelligent

# 11 INADEQUATE TRAY ADHESION

# 11 INADEQUATE TRAY ADHESION

## PROBLEM

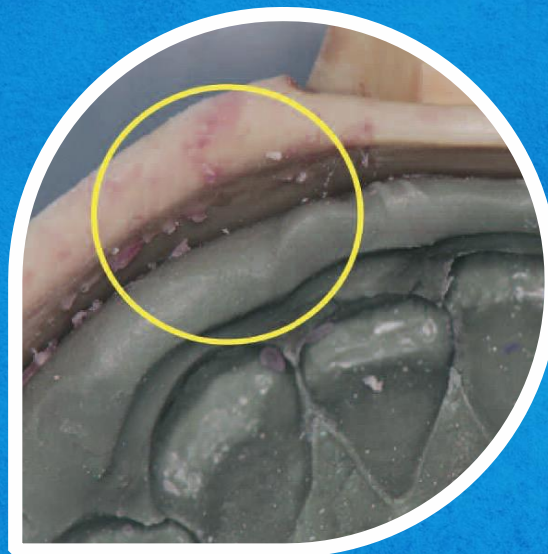- Tray adhesive not used or applied properly.
- The impression material can shrink away from the tray causing distortion that results in a reproduction smaller than the tooth.
- The tray is no longer supportive of the impression material and distortion could result upon pouring.



# 11 INADEQUATE TRAY ADHESION

## PROBABLE CAUSES

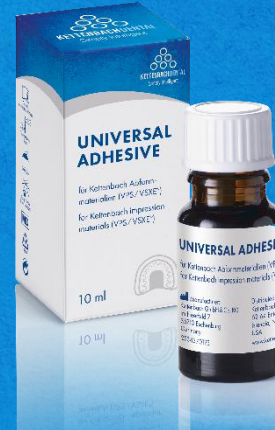- No / not enough tray adhesive
- Incompatible / wrong manufacturer's adhesive
- Inadequate drying time for adhesive
- Outdated / expired tray adhesive
- Disinfectant residue



# 11 INADEQUATE TRAY ADHESION

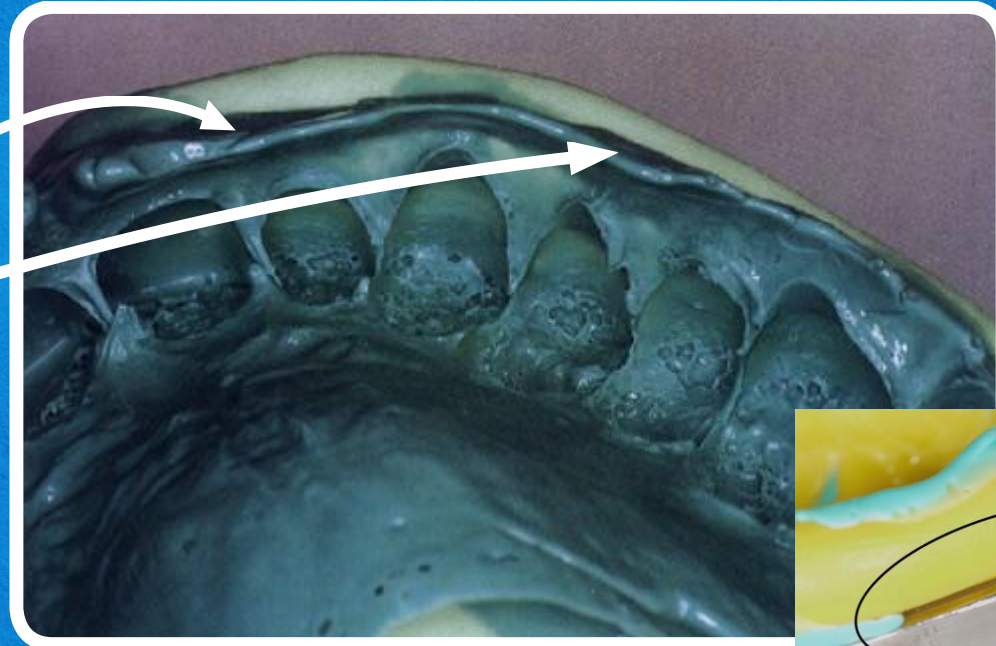
## SOLUTION

- Use tray adhesive recommended by manufacturer.
- Apply even coat of adhesive to tray covering all areas of contact between tray and impression material.
- Allow 5 minutes to dry.



# 11 INADEQUATE TRAY ADHESION

Lack of adhesion



Formation of bubbles.

The impression was removed from the mouth before the impression material had completed the polymerization process.



**KETTENBACHDENTAL**

Simply intelligent

# 12 GLOVE & HEMOSTATIC AGENT SELECTION

# 12 GLOVE & HEMOSTATIC AGENT SELECTION

- Aluminum chloride and ferric sulfate containing hemostatic agents interfere with the set of vinylpolysiloxane (VPS) materials.
- Sulfur-contaminated gloves cause the impression materials setting process to slow down or be inhibited. Hypoallergenic gloves tend to be best. Do not use latex gloves.



# 13 SURFACE INHIBITION / WASH SLOW SETTING

# 13 SURFACE INHIBITION / WASH SLOW SETTING

## PROBLEM

- The surface of the impression material is not set, tacky to the touch, and visually resembles the surface of an orange peel.
- Unset impression material residue may be transferred from the impression to the die stone during model pouring. Wash slow setting.



# 13 SURFACE INHIBITION / WASH SLOW SETTING

## PROBABLE CAUSES

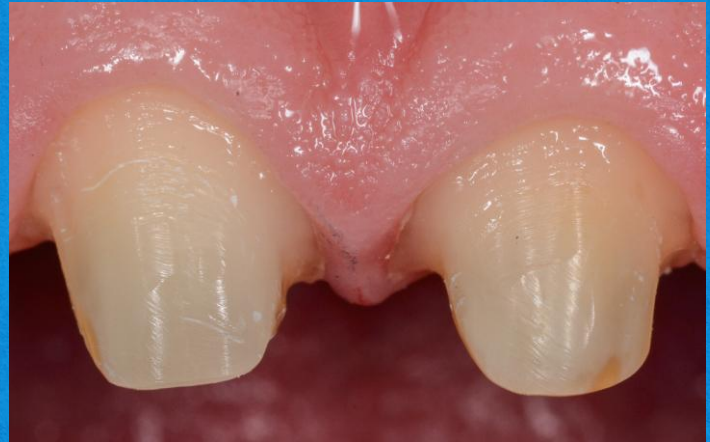- Latex glove/rubber dam inhibition
- Touching the prepared teeth or surrounding tissues, rolling retraction cord in gloved fingers, or the use of a rubber dam may transfer sulfur to critical areas of the impression; causing site specific inhibition
- Exposure to residues from custom temporary materials
- Exposure to air inhibited methacrylates (composites, adhesives, core buildup materials)
- Cartridge plugging
- Product beyond its expiration date
- Product is exposed to high heat and not stored properly
- Use of wrong mixing tip



# 13 SURFACE INHIBITION / WASH SLOW SETTING

## SOLUTION

- If contamination is suspected, scrub affected area with diluted hydrogen peroxide prior to making the final impression.
- If temporary is made prior: Remove air inhibited layer on the exposed surface with an alcohol wipe before making the final impression.
- Fabricate the temporary crown or bridge after the final impression has been made.
- Use manufacturer suggested mixing tips.
- Check expiration of material and make sure material is stored properly.

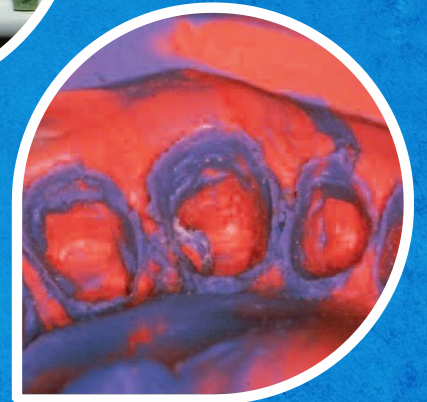

**14 NOT ENOUGH WASH  
MATERIAL & TOOTH  
CONTACT WITH TRAY**

# 14 NOT ENOUGH WASH MATERIAL & TOOTH SLOW SETTING

## PROBLEM

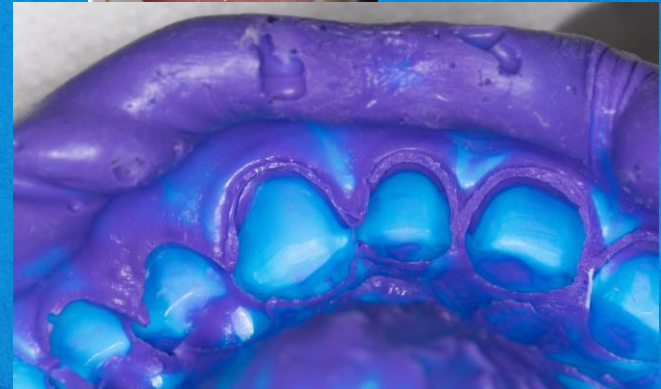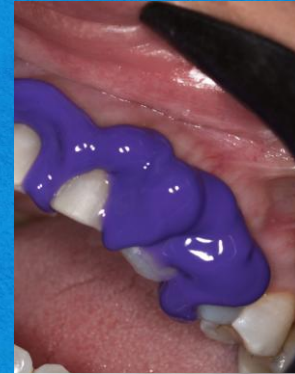- Unable to capture all the detail needed
- Will not be able to support the weight of the die stone when pouring



# 14 NOT ENOUGH WASH MATERIAL & TOOTH SLOW SETTING

## SOLUTION

- Fill tray 2/3 full
- Use more wash material around preparation and adjacent teeth
- Use custom tray or 2-step putty/wash in a stock tray





**KETTENBACHDENTAL**

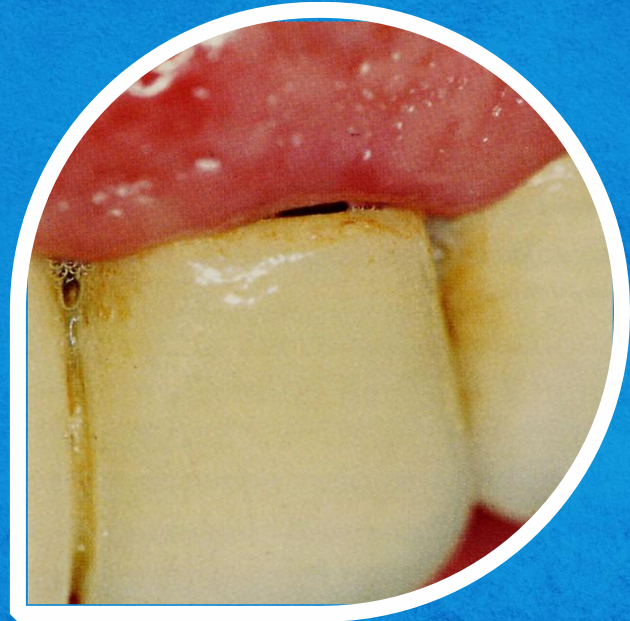
Simply intelligent

# 15 TIGHT FITTING CROWNS

# 15 TIGHT FITTING CROWNS

## PROBLEM

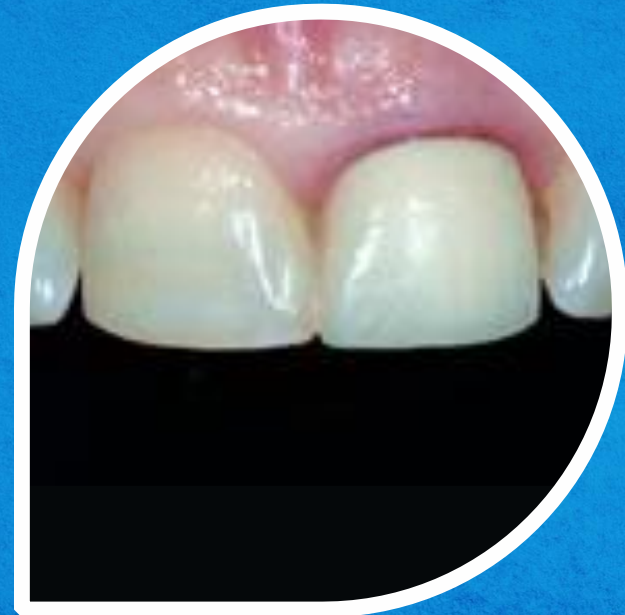- Tight crowns
- Short crowns



# 15 TIGHT FITTING CROWNS

## PROBABLE CAUSES

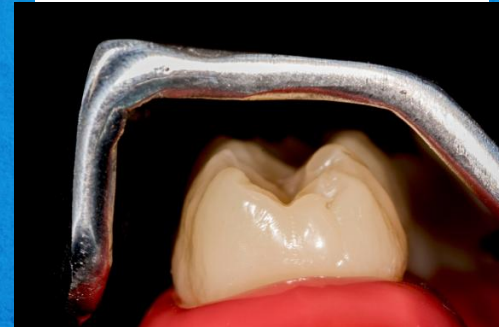- Early mouth removal
- Seating partially set impression material
- Poor bond of material to tray
- Insufficient tray support (weak or low tray walls)
- Teeth in contact with tray and/or not adequately relieving pre-set impression material
- Insufficient die trimming



# 15 TIGHT FITTING CROWNS

## SOLUTION

- Insufficient Tissue Management.
- Closely follow product recommendation for oral setting time.
- Always use a VPS tray adhesive and allow to dry as per product instructions.
- Use custom or inflexible (preferably metal) stock trays.
- Avoid contact of teeth with tray, or pre-set tray material.
- For two step technique use a hard tray material and eliminate undercuts.
- Consult with dental laboratory.





**KETTENBACHDENTAL**

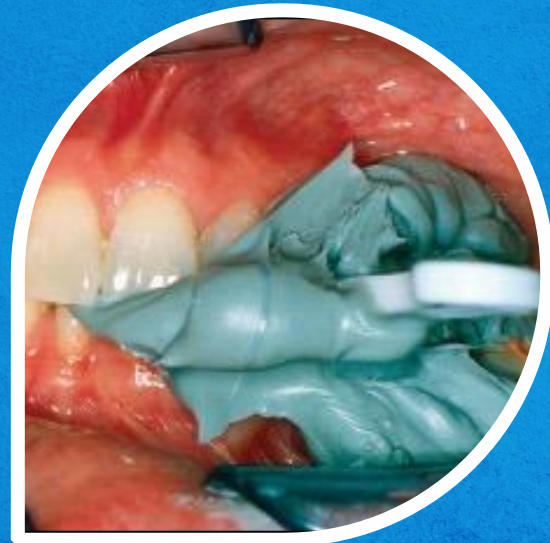
Simply intelligent

# 16 DOUBLE BITE TECHNIQUE

# 16 DOUBLE BITE TECHNIQUE

## PROBLEM

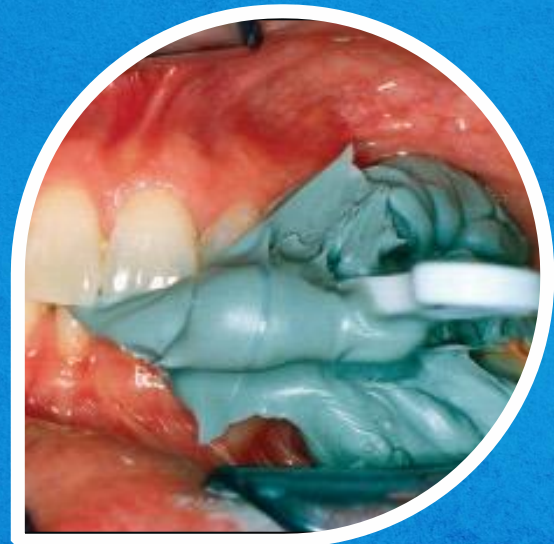
- Short crown margins
- Occlusal adjustment too high
- Crowns too tight or too small



# 16 DOUBLE BITE TECHNIQUE

## PROBABLE CAUSES

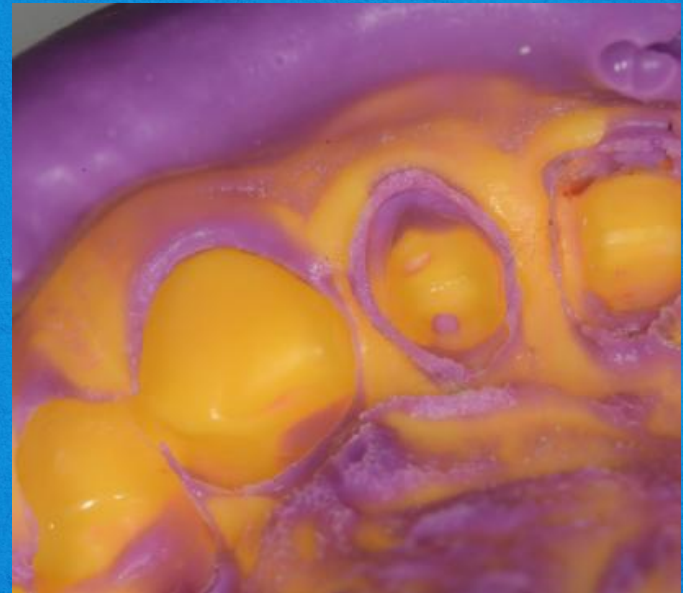- Teeth in contact with tray
- Poor tissue retraction and/or moisture control
- Early removal from mouth
- Patient not in centric occlusion
- Lack of tray support/weak tray/no walls



# 16 DOUBLE BITE TECHNIQUE

## SOLUTION

- Insufficient Tissue Management
- Avoid contact of teeth with tray.
- Use double cord retraction technique.
- Follow recommended oral setting time.
- Try-in tray prior to making the impression.
- Establish repeatable orientation of the teeth.
- Identify contact areas or distinguishing features.
- Ensure that the crossbar does not interfere with achieving complete occlusion.
- Use rigid impression tray with walls.





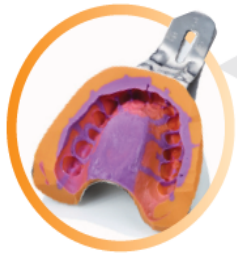**KETTENBACHDENTAL**

Simply intelligent

# 17 PANASIL

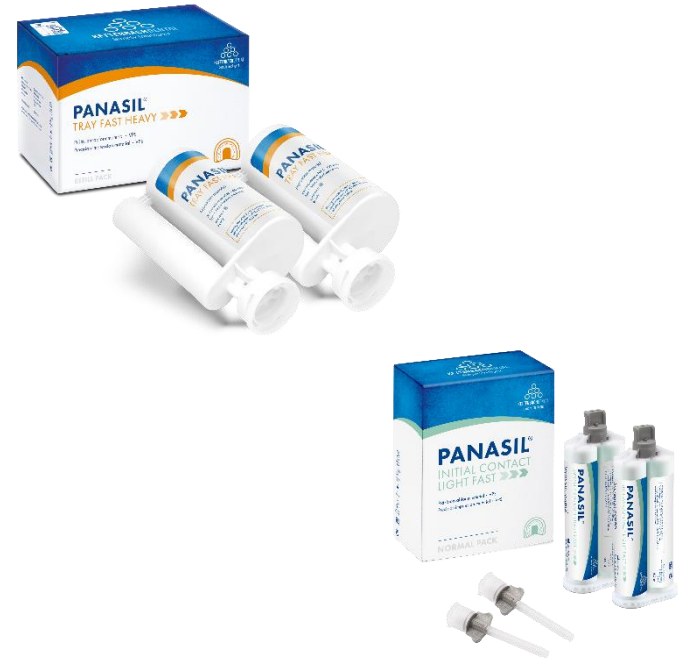# 17 PANASIL

**Panasil®** – Precise, predictable impressions



A wide range of choices for a wide range of indications.

- > Exceptional hydrophilicity
- > High tear strength
- > Dimensional accuracy
- > High resistance to permanent deformation

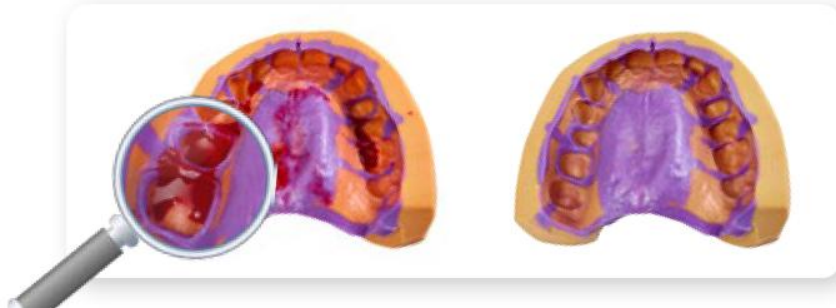

# 17 PANASIL

## More control of moisture than any other impression material!

No need to completely Dry the Prep - Because our material is more moisture efficient (hydrophilic) than any other PVS or Polyether on the market!

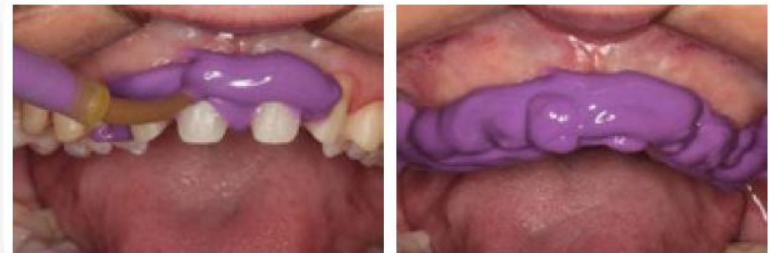This saves you considerable time, and the frustration of getting those bleeders completely dry on those difficult cases!



## More control of syringable light body!

Light body that is less likely to slump or drip because it is “uniquely” designed to flow under pressure!

This means if you are working on a difficult case, or have that patient that has a gag reflex, then you have better control!



Photos courtesy of Dr. Ross Nash

# 17 PANASIL TIP GUIDE

> Remove any contaminants prior to taking final impression. Products containing sulfur, aluminum chloride, ferric sulfate, inhibit the polymerization of all PVS materials and need to be rinsed thoroughly prior to taking the final impression. (Residue left behind from temp fabrication or injectable hemostatic pastes need to be removed with an alcohol soaked pellet.)

> Don't desiccate the area, works best in a wet environment. Leave the prep area and surrounding teeth glistening.

> Keep mixing tip submerged in the material

> Don't blow air on the material

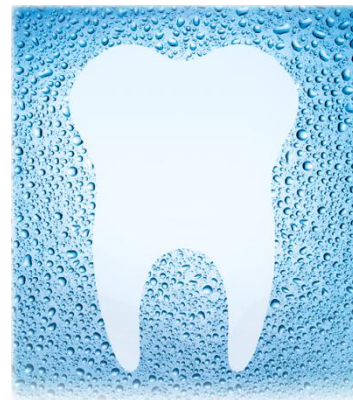> Don't exceed the intraoral working time of the wash material

> Don't exceed the working time of the tray material

> Synchronize filling and seating of tray with the completion of syringing teeth.

> Use the tips that come with the material  
(match color of cap to color of tip)

> Keep the used mixing tip on used cartridge until the next procedure.



▶ Fast 30 sec. / Regular 1:00 min.

▶ Fast 1:00 min. / Regular 2:00 min

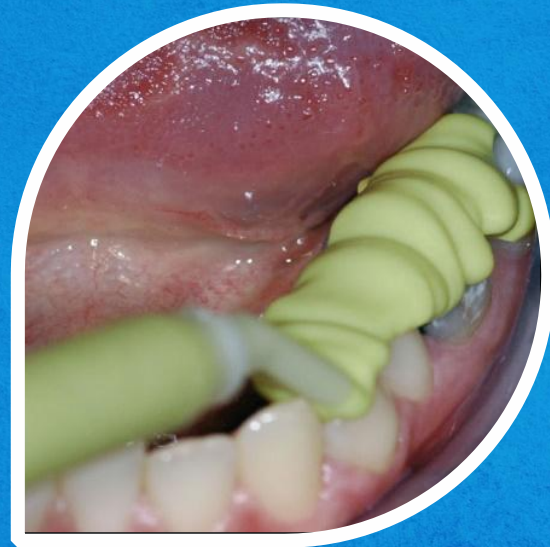

# 18 BITE REGISTRATION

# 18 BITE REGISTRATION

## PROBLEM

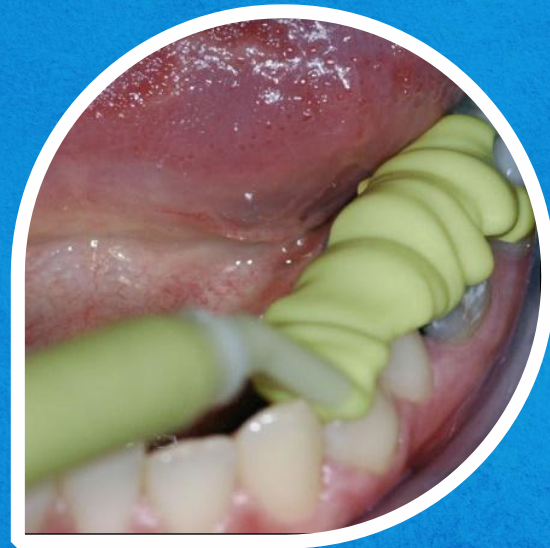- Difficulty in establishing vertical and horizontal relationships of the dental arches to the mounted stone casts
- Excessive occlusal adjustment



# 18 BITE REGISTRATION

## PROBABLE CAUSES

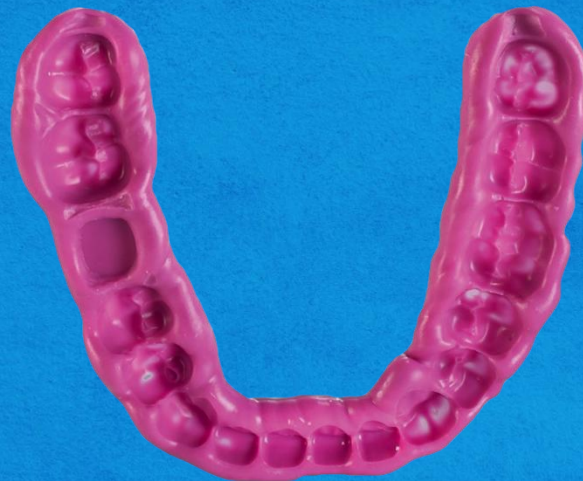- Bite registration not provided
- Poor interocclusal record



# 18 BITE REGISTRATION

## SOLUTION

- Provide a rigid and dimensionally stable bite registration with each case.
- Properly trim a good bite registration material (with high final hardness).
- Use dimensionally stable bite registration material (prefer a-silicone).
- Ensure that the patient does not move during the procedure.
- Note working time of the bite registration material.





**KETTENBACHDENTAL**

Simply intelligent

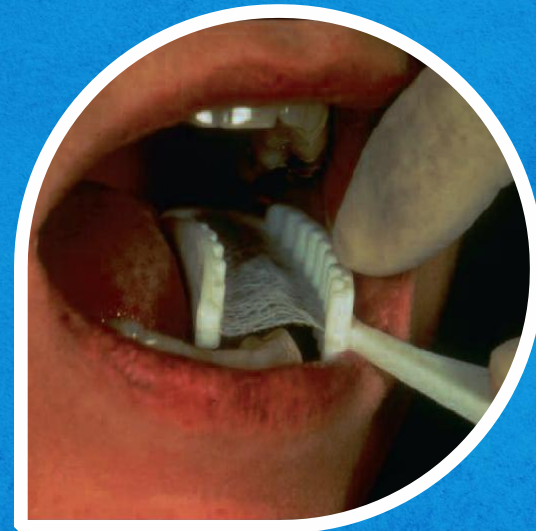# 19 PATIENT EDUCATION

# 19 PATIENT EDUCATION

## EDUCATION

### PRACTICE INSERTION

- Seat the tray without adhesive or impression material and instruct patient how to close into centric occlusion.
- Be particularly vigilant when recording a bite record unilaterally as the patient may go into lateral excursion on that side.
- Instruct patients that once the tray is seated they should refrain from any movements that could shift the position of the tray, thereby distorting the impression material at a critical phase during its set.





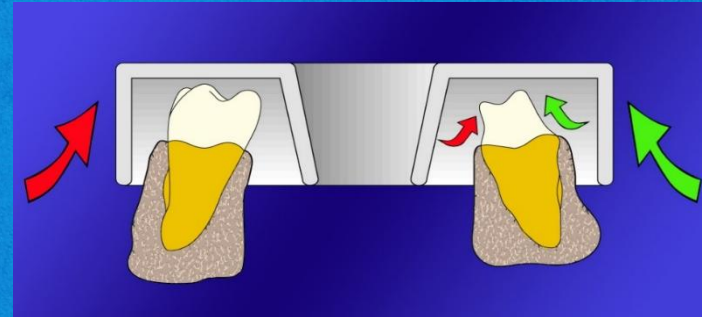
**KETTENBACHDENTAL**

Simply intelligent

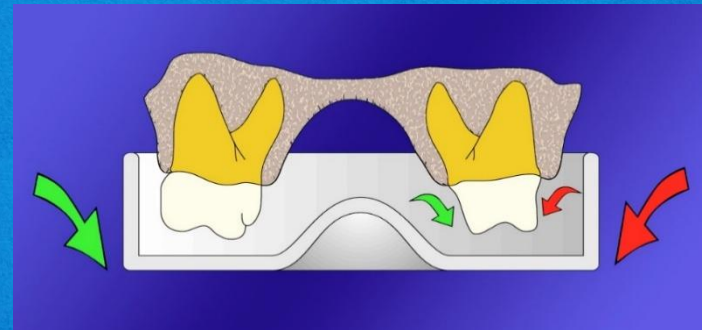
# 20 SEATING & REMOVAL OF THE TRAY

# 20 SEATING & REMOVAL OF THE TRAY


- Retract cheek bilaterally when seating, even for a triple tray impression, since a patient may favor the retracted side when closing and not close into centric occlusion.
- Position the tray before seating. The tray should be aligned parallel to the occlusal plane to ensure vertical seating.
- Use a slow continuous vertical seating motion.
- For a closed bite have patient close into centric occlusion.
- The patient should perform no jaw movement until the impression is ready to be removed.
- After mouth removal time relieve pressure peripherally and remove tray by grasping handle and quickly snapping from sealed position.



On the lower arch, the first movement for removal must be made on the preparation side.



On the upper arch, this first movement must be made on the opposite side to the preparation.



**KETTENBACHDENTAL**

Simply intelligent